



# Transforming the Future

2014-2015 Cancer Care Annual Report  
Focus on Germ Cell Tumors



**Children's Mercy**  
KANSAS CITY



## Table of Contents

Cancer Registry.....	4
Germ Cell Tumors.....	6
<b>Harper Atkinson .....</b>	<b>10</b>
General Surgery.....	12
Pathology .....	14
Radiology .....	15
Cytogenetics .....	16
Gynecology.....	18
Urology .....	20
Genomics and Biorepository .....	22
Advanced Practice Nurses.....	23
FaCT Team .....	24
Survive & Thrive .....	26
<b>Fertility Preservation.....</b>	<b>27</b>
<b>Facility Dog Program .....</b>	<b>28</b>
Annual Report Contributors .....	30

Learn more about our bubbly cover girl,  
**Harper Atkinson**, on page 10.



We are pleased to present our annual report from the Children's Mercy Cancer Program. The focus this year is on germ cell tumors, a rare cancer type representing about 3 percent of pediatric cancers.

This report illustrates our multidisciplinary approach to pediatric cancer care. With numerous other specialists like our surgeons, radiologists and pathologists who join forces with pediatric oncologists, our multi-specialty interdisciplinary model of care makes the diagnosis and treatment of children with cancer as seamless as possible.

By introducing you to our program, some of our staff, and some of our patients, we believe that you will understand why we are so proud of our accomplishments.

Visit our website, [childrensmercy.org](http://childrensmercy.org), to learn even more about our hospital and programs.

**Maxine L. Hetherington, MD**

Editor

Principal Investigator, Children's Oncology Group  
Children's Mercy Kansas City

Associate Professor of Pediatrics

University of Missouri-Kansas City School of Medicine

**Alan S. Gamis, MD, MPH**

Associate Division Director, Section of Oncology  
Children's Mercy Kansas City

Professor of Pediatrics

University of Missouri-Kansas City School of Medicine

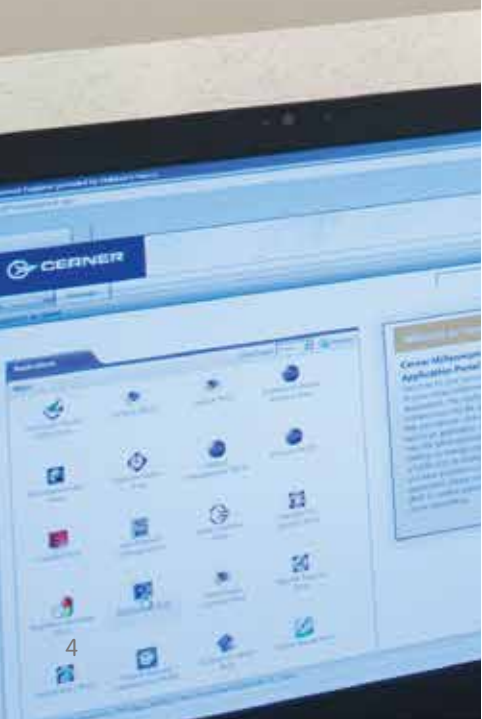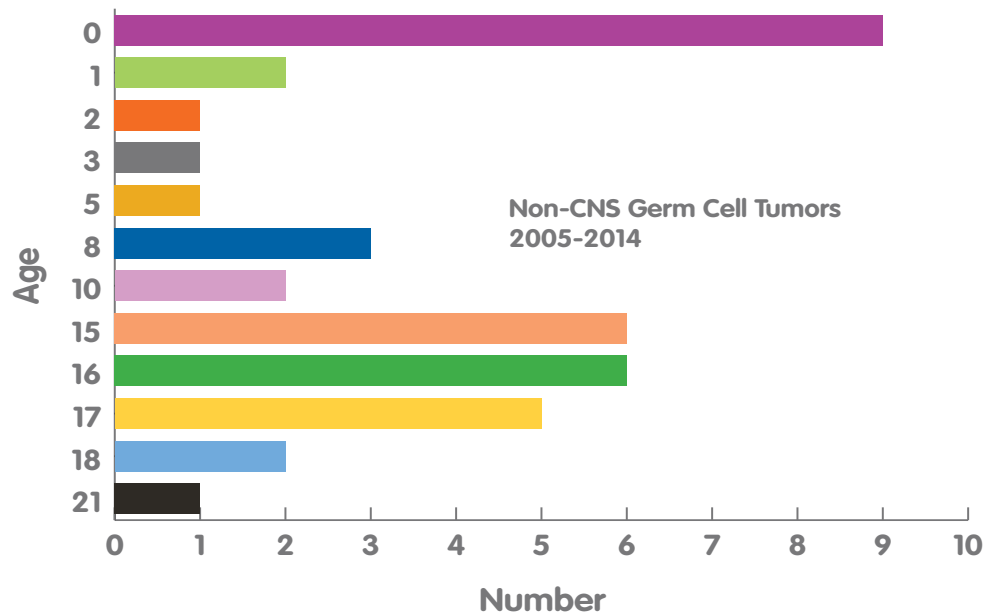


# Cancer Registry Review 2014

The Cancer Registry at Children's Mercy Kansas City is an important part of our care. The registry is a database of confidential information concerning all malignancies, benign brain tumors and other specified conditions. The database is operated under the guidance of the Cancer Care Committee, with accreditation approval maintained by the American College of Surgeons Commission on Cancer. All data about diagnosis, treatment, recurrence and survival must be collected in standardized detail. Reporting is required by state and federal law, as a means of comprehensive cancer prevention and control programs.

Follow-up of cancer patients is an important part of the registry activities. Knowing outcomes helps the medical staff evaluate the best treatment and the long-term effects of treatment. Follow-up letters are sent out on a regular basis. Parents and older patients also may contact the registry by secure email at [cancerregistry@cmh.edu](mailto:cancerregistry@cmh.edu) to discuss follow-up. All of the registry operations are conducted according to the Health Insurance Portability and Accountability (HIPAA) privacy regulations.

**Age at Diagnosis (Years)**

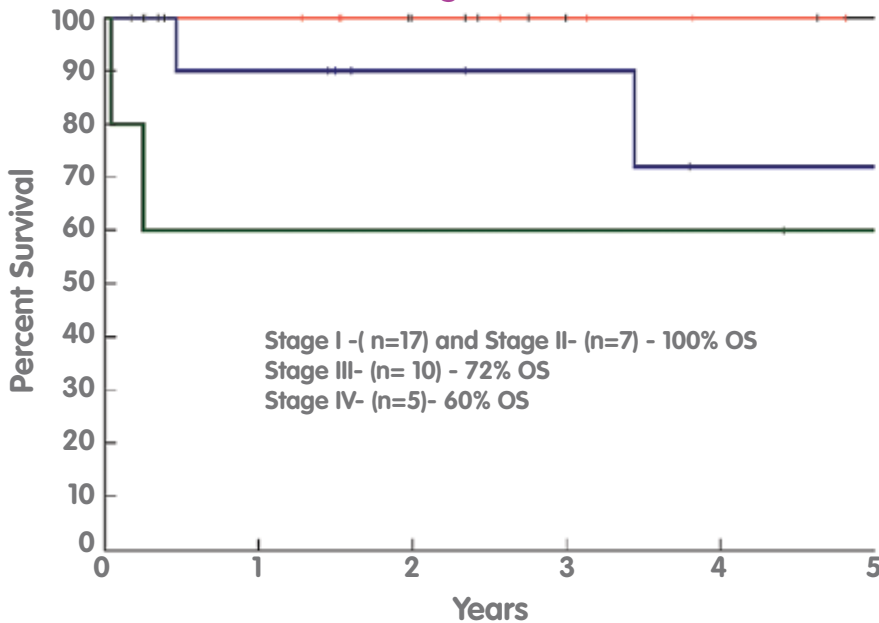


During 2014, the Cancer Registry added **195** patients. Of these patients, there were **167** patients who were diagnosed with malignancies and benign central nervous system tumors. There were **28** patients added to the registry with benign reportable conditions. These conditions are collected at the request of the Cancer Care Committee for surveillance purposes and are not required to be reported outside our facility. The Frequency of Diagnosis chart shows a breakdown of disease types.

## Frequency of Diagnosis 2014

Diagnosis	Totals	Percentage
<b>Central Nervous System</b>	<b>50</b>	<b>26</b>
Astrocytoma	12	
Glioma	10	
Medulloblastoma	8	
Ependymoma	3	
Atypical Malignant Rhabdoid Tumor (ATRT)	1	
Glioblastoma	2	
Choroid Plexus Carcinoma	1	
Primitive Neuroectodermal Tumor (PNET)	3	
High Grade Tumor with Differentiation	1	
Pleomorphic Sarcoma, Undifferentiated	1	
Benign Borderline CNS	8	
<b>Leukemia</b>	<b>48</b>	<b>25</b>
ALL	36	
AML	12	
<b>Lymphoma</b>	<b>15</b>	<b>8</b>
Non-Hodgkin	12	
Hodgkin	3	
<b>Kidney</b>	<b>7</b>	<b>4</b>
Wilms	6	
Malignant Rhabdoid Tumor	1	
<b>Neuroblastoma</b>	<b>11</b>	<b>6</b>
<b>LCH</b>	<b>8</b>	<b>4</b>
<b>Germ Cell</b>	<b>5</b>	<b>2</b>
<b>Bone Tumors</b>	<b>5</b>	<b>2</b>
<b>Rhabdomyosarcoma</b>	<b>3</b>	<b>1</b>
<b>Non-Rhabdo Soft Tissue</b>	<b>4</b>	<b>2</b>
<b>Other Malignant</b>	<b>11</b>	<b>5</b>
Hepatoblastoma	2	
Refinoblastoma	1	
Thyroid Carcinoma	3	
Hepatocellular Carcinoma	2	
Various Other	3	
<b>Benign Reportable Conditions</b>	<b>28</b>	<b>15</b>
Teratoma, Benign	10	
Desmoid Tumor	4	
TMD- Transient		
Myeloproliferative Disorder	3	
JXG – Juvenile Xanthogranuloma	2	
Ganglioneuroma	3	
HLH- Hemophagocytic		
Lymphohistiocytosis	2	
Inflammatory Myofibroblastic Tumor	1	
Plexiform Neurofibroma	1	
Juvenile Granulosa Cell	2	
<b>TOTAL</b>	<b>195</b>	<b>100%</b>


### Five Year OS by Stage - Germ Cell Tumors (Patients Diagnosed 2005-2014)



### Geographic Locations of Non-CNS Germ Cell Patients at Diagnosis





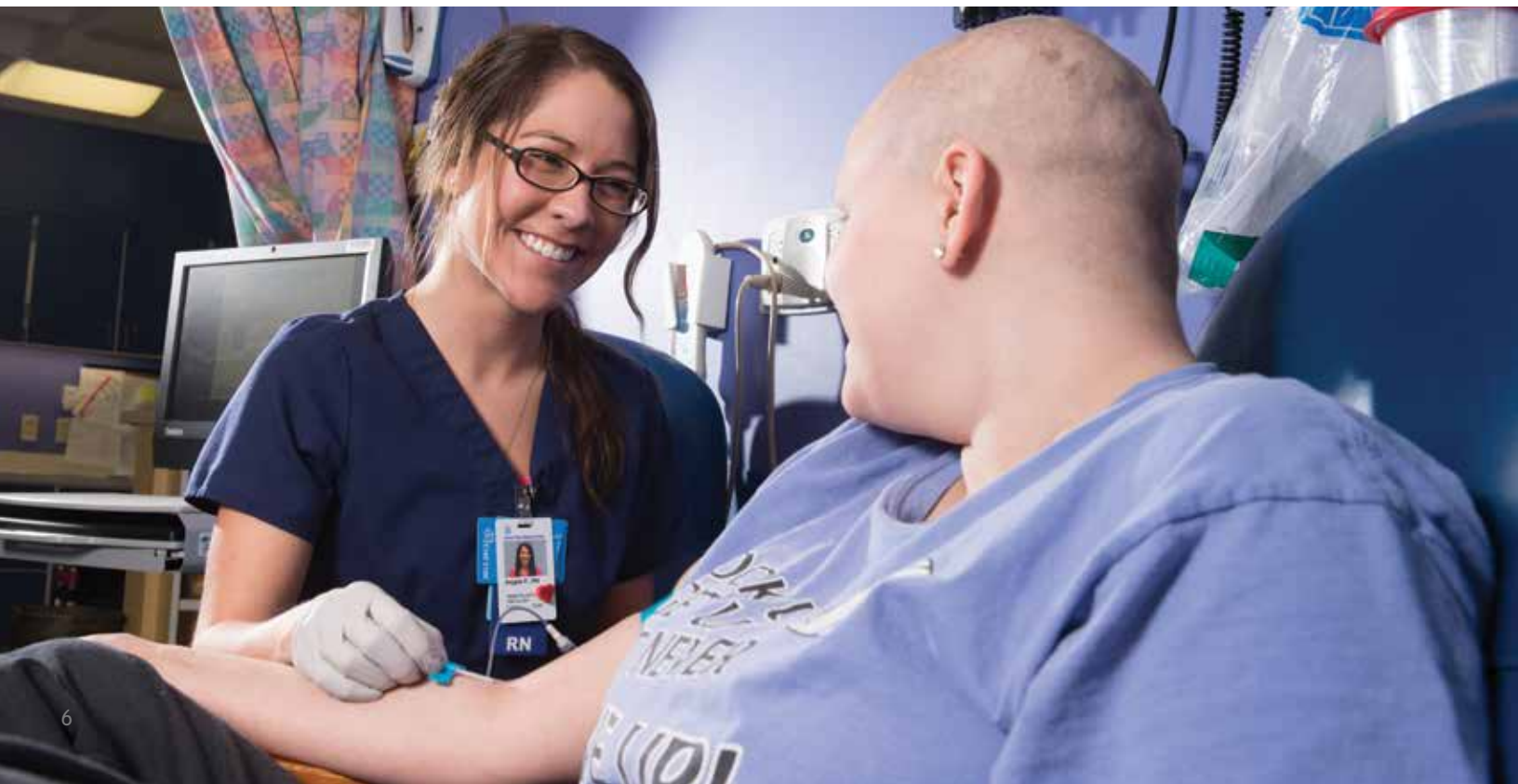

## Germ Cell Tumors

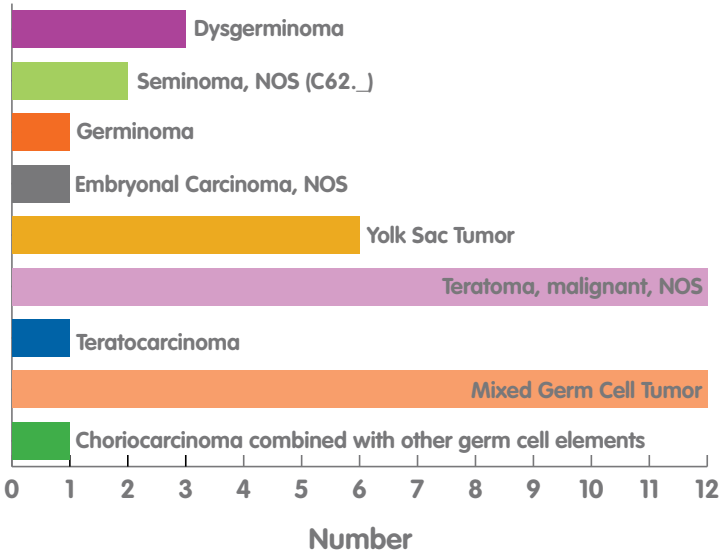
Germ cell tumors (GCTs) are challenging. They affect the entire spectrum of pediatric patients, from newborn infants to young adults. About 900 children and adolescents are diagnosed with GCTs in the U.S. each year, about 4 percent of all childhood cancers. GCTs are the most common solid tumor diagnosed in young adults.

Germ cell tumors are histologically diverse, ranging from benign masses to life-threatening malignant tumors, capable of spread from the primary tumor to other parts of the body. Although the majority of GCTs occur in the ovaries and testicles, they can occur throughout the rest of the body in extragonadal sites.

Presenting symptoms depend upon the tumor's location. A testicular GCT begins as a painless mass in the scrotum. Ovarian and abdominal tumors can present with abdominal pain, constipation or a palpable abdominal mass. Mediastinal tumors are in the area between the breastbone



### Type of Non-CNS Germ Cell Tumors at Children's Mercy by Histology



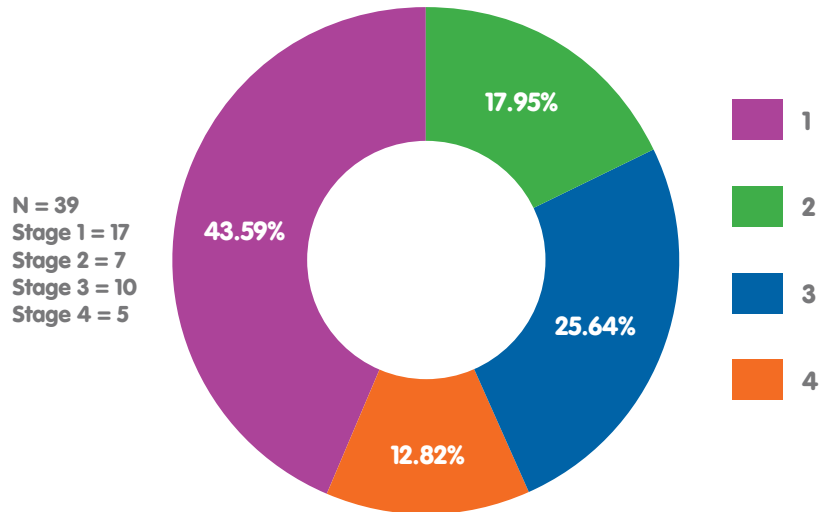
and spinal column, and can cause chest pain or shortness of breath or wheezing from compression of the windpipe. Sacrococcygeal tumors are often found in infants. They arise from the tissue above the tailbone, and can extend either externally and can be seen on prenatal ultrasound or at birth, or can extend internally, causing constipation, urinary retention or pain. GCTs affecting the brain can present with visual disturbances, headache or vomiting.

Some of these tumors are easily palpable on physical examination. Imaging studies can be done to evaluate the primary tumor and to determine if the tumor has spread to other parts of the body through either the lymphatic pathways into lymph nodes, or the bloodstream to distant parts of the body such as the lungs, liver, bones or brain. Malignant tumors can produce specific chemical markers such as alpha fetoprotein (AFP) and beta human chorionic gonadotropin (B-HCG) that can be found in elevated levels in the blood.

Benign teratomas contain all mature, normal kinds of tissue, including bone, cartilage, hair, fat and teeth. They can be cured with surgical excision, with

less than 10 percent chance of recurrence. When teratomas have been completely resected, they are evaluated to determine if any abnormal, immature, malignant tissue is mixed in with the normal mature tissue. If AFP or B-HCG levels are elevated prior to surgery, it is presumed that there is some malignant component to the tumor. Following surgery, if tumor markers normalize, additional therapy may not be necessary. If there is a malignant tumor of the ovary or testicle that is removed, without evidence of tumor spread by staging studies, there is up to a 50 percent chance of tumor recurrence. If active surveillance rapidly diagnoses recurrent tumor, more than 90 percent of children with recurrent tumor can be cured with chemotherapy. If there is known macroscopic residual malignant tumor, chemotherapy is administered. Radiation therapy is used most commonly in children who have GCTs affecting the brain or spinal cord.

### Children's Oncology Group (COG) Staging of Non-CNS Germ Cell Tumors at Children's Mercy



The most common treatment regimen in adults is a combination of bleomycin, etoposide and cisplatin, termed BEP. It has been used for more than 40 years, and transformed metastatic testicular cancer in adults from virtually incurable to about 90 percent curable. The treatment regimen has been modified in children to reduce the use of bleomycin, and to shorten the treatment in the majority of patients,

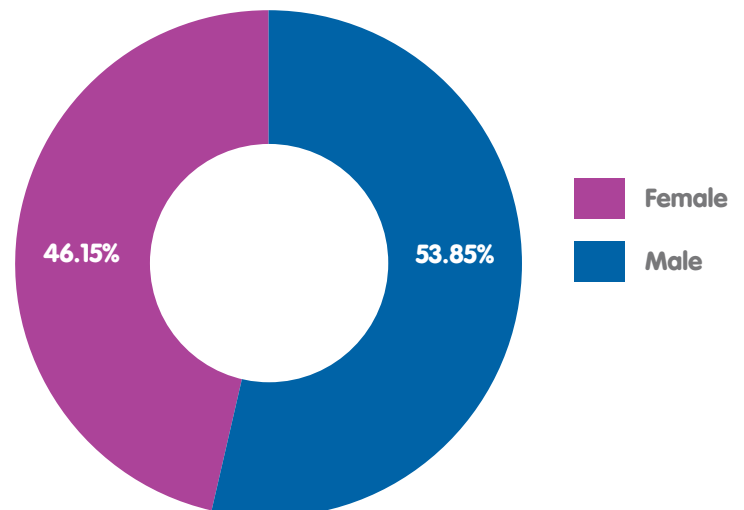


called PEB. Although the BEP regimen has been very successful in adults, there are many known side effects. Secondary malignancies occur in as many as 47 percent of long-term survivors. Radiation therapy contributes to an increased incidence of secondary malignancy. The use of etoposide is associated with secondary leukemia. Bleomycin can result in pulmonary insufficiency. Cisplatin can result in reduced kidney function, renal salt-wasting, hearing loss and tinnitus. Infertility can be an issue because of surgery, chemotherapy or radiation therapy. There is an increased incidence of cardiovascular disease in the adult survivors of testicular cancer.

The causes of childhood GCTs are not known. However, we do recognize that males with undescended testicles have an increased risk to develop testicular GCTs. Some genetic syndromes characterized by extra or missing sex chromosomes can be associated with an increased incidence of germ cell tumors. Men who use muscle-building supplements that contain creatine or androstenedione may have up to 65 percent increased risk of developing testicular cancer.

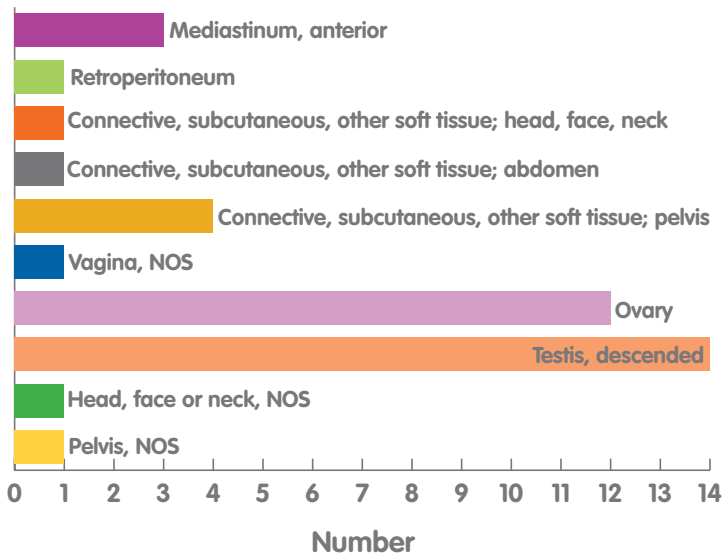
**Sex of Patients with Non-CNS Germ Cell Tumors at Children's Mercy**

N = 39  
Males = 21  
Females = 18





### Anatomic Site of Non-CNS Germ Cell Tumors at Children's Mercy

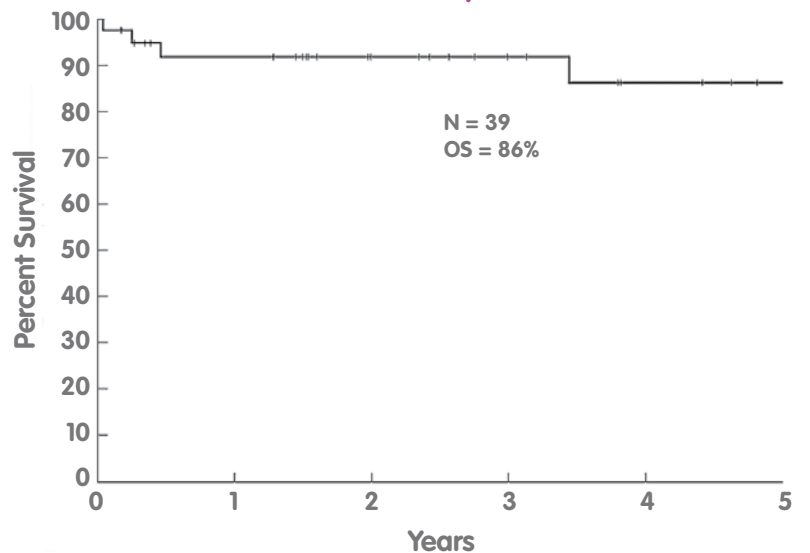


Since we don't know many of the causes for childhood GCTs, prevention is impossible. It is recommended that boys with undescended testicles undergo orchiopexy to reduce the risk of the development of testicular tumors later in life. Teaching young men that testicular cancer is the most common cancer of adolescents and young men may allow for more rapid recognition of tumors, prior to systemic spread.

Clinical trials are used routinely in pediatric oncology to improve cure rates and reduce long-term side effects of therapy. However, participation in clinical trials is far less common in adults, especially in newly diagnosed GCTs, in which the cure rate is so good with standard therapy. Many different practitioners care for young adults with GCTs, including pediatric oncologists, medical oncologists, gynecologic oncologists and urologic oncologists. It's been hard to get this diverse group of physicians to collaborate, but collaboration is on the horizon. Clinical trials for standard risk, high risk and recurrent germ cell tumors are in the works. Since GCTs are so rare, international research collaboration is also being discussed.

“Germ cell tumors are the most common solid tumor diagnosed in young adults.”

### Overall Five Year Survival of Non-CNS Germ Cell Patients at Children's Mercy - 2005-2014





# Harper Atkinson

After a seemingly normal pregnancy, Mandi and Daniel Atkinson didn't expect anything unusual following the birth of their first daughter, Harper. However, something abnormal caught the eye of the family's OB-GYN immediately following her birth.

"The doctor noticed very quickly that there was a lump on her lower back stemming from her tailbone," said Mandi. "We were sent to Children's Mercy where they did an MRI."

From the results, doctors concluded Harper had a tumor—a sacral teratoma.

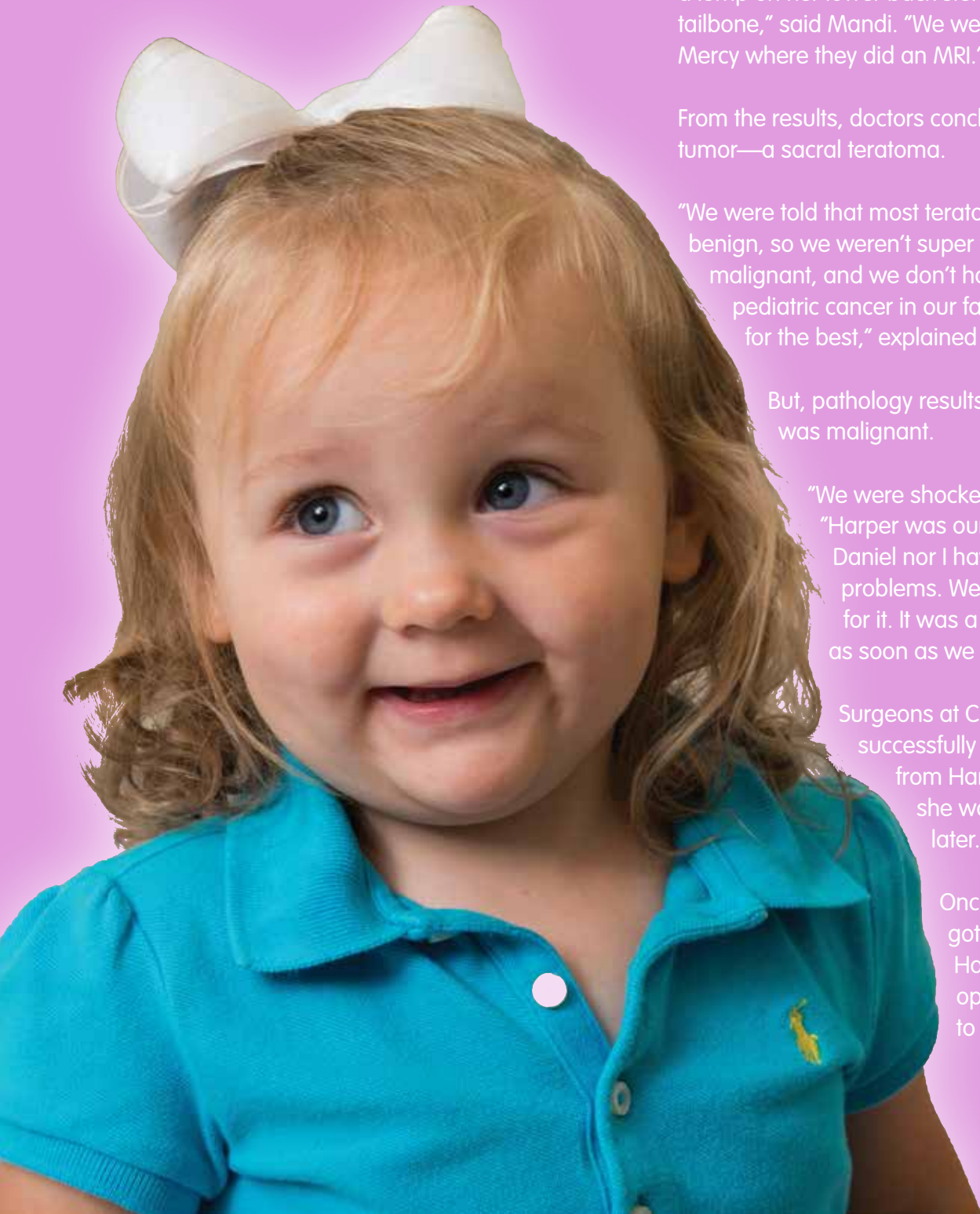"We were told that most teratoma tumors are benign, so we weren't super worried about it being malignant, and we don't have any history of pediatric cancer in our family, so we just hoped for the best," explained Mandi.

But, pathology results concluded the tumor was malignant.

"We were shocked," said Mandi. "Harper was our first child and neither Daniel nor I have any medical problems. We just weren't prepared for it. It was a whirlwind of events as soon as we got the diagnosis."

Surgeons at Children's Mercy successfully removed the tumor from Harper's tailbone and she was discharged a week later.

Once the Atkinsons finally got their newborn home, Harper's incision split open, forcing them back to the emergency room.



"We were home less than 24 hours before returning to the hospital for another week, so we had a little bit of a rocky road to start with," said Mandi.

When Harper was admitted to the hospital for a second time, the Atkinsons were introduced to Maxine Hetherington, MD, Pediatric Hematologist/Oncologist.

"We recommended holding off on chemotherapy," explained Dr. Hetherington. "Harper's alpha-fetoprotein (AFP) level was extremely high, which is common right after birth, but can also indicate a malignant tumor. We went with our gut feeling and observed Harper after surgery in hopes that the tumor had been completely removed."

"In the beginning, labs were showing that her AFP level was going down really well, but stopped going down as rapidly as we would've hoped around her two-month mark," said Mandi.

At that time, it was up to Dr. Hetherington to decide what the best plan of action was: continue observation, or move on to chemotherapy? Harper's AFP level remained exceedingly high, sparking concern that a piece of the tumor may have been missed in surgery. Because of this, Dr. Hetherington consulted with other pediatric oncologists and experts in the treatment of malignant germ cell tumors. They recommended Dr. Hetherington and her team hold off on chemotherapy, advising them to remain patient. Instead, they scheduled monthly check-ups to monitor Harper's AFP level.

"Those were some trying months of waiting it out and praying that her AFP level went down instead of up," said Mandi. "But we've got a lot of trust in Dr. Max and her team—they've never led us astray and we had wonderful care the whole time we were there."

"I can't say enough about the NICU nurses Harper had during our stay. They were wonderful," Mandi said. "We have the same nursing and tech staff every time we come back, which has been great. I don't want to say that we look forward to going, because we don't, but it's not nearly as painful when you know you have great people taking care of you."

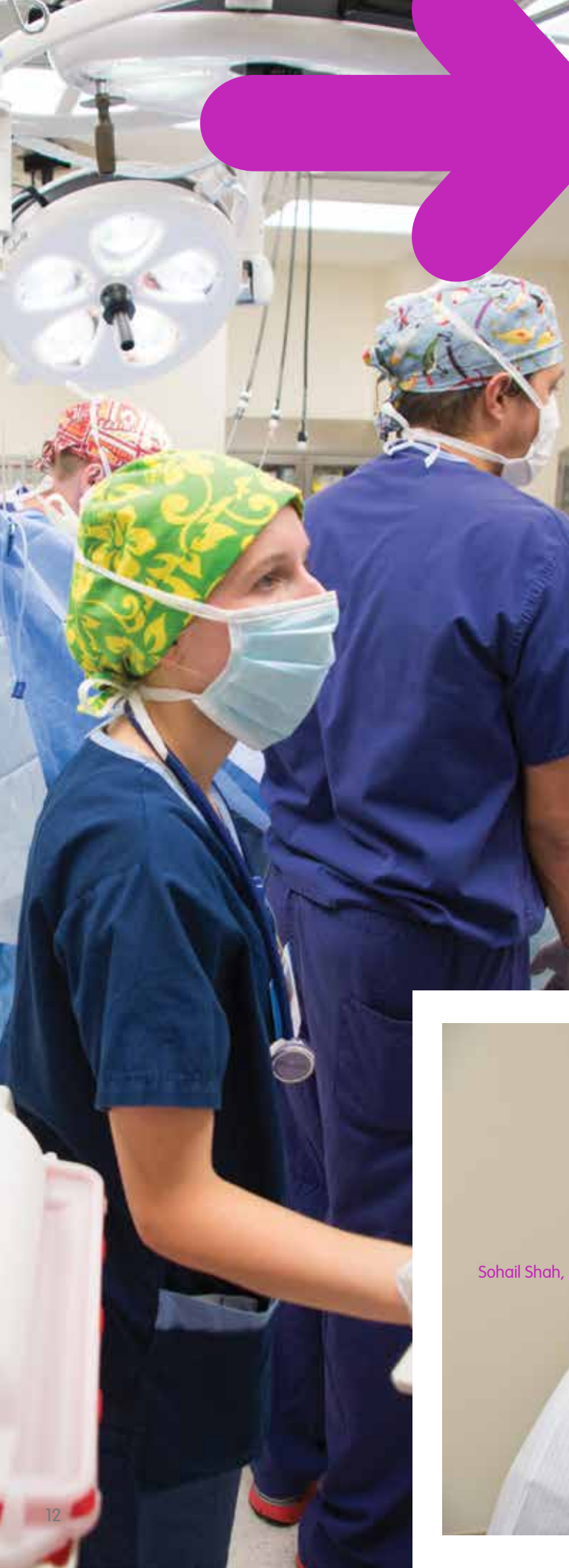

Harper during a check-up with Maxine L. Hetherington, MD

Harper is now nearly 2 ½ and hasn't looked back since surgery. She continues to have regular check-ups and monitoring of her AFP level.

"We've followed up with the oncology department every month faithfully to check labs. We hope to decrease the frequency of check-ups because that would mean her lab results are more normal than before," Mandi said. "No one would ever know anything was ever wrong with Harper at this point—she's hit all of her milestones to date."





# General Surgery

Pediatric germ cell tumors are a heterogeneous group of neoplasms generally divided into gonadal and extragonadal types. The most common type of germ cell tumor is the teratoma. Teratomas that occur in infancy are usually extragonadal, while those occurring in older children and adolescents most often are found in the testis or ovaries. The current treatment of pediatric germ cell tumors consists of surgical resection and selective chemotherapy.

Pediatric general surgeons are experienced in the management of both gonadal and extragonadal tumors. The gonadal germ cell tumors are also often managed by our pediatric urology and pediatric gynecology colleagues. However, the surgical management of extragonadal germ cell tumors is primarily provided by pediatric general surgeons.

The surgical treatment is determined by the location and extent of the tumor. The recommendations for specific sites of extragonadal germ cell tumors are:



Sohail Shah, MD

**Sacroccygeal teratoma:** This is the most common tumor in the newborn, and is the most common germ cell tumor overall. It is often diagnosed by routine prenatal ultrasound. Repeat imaging is often used to follow in-utero progression and further determine the size, location, complexity, and extension. Depending on tumor presentation, some of these are not diagnosed until later in childhood, and these are more often malignant. Complete surgical excision remains the initial treatment of choice. Tumors that are deemed to be unresectable upon initial presentation are biopsied and followed with chemotherapy. An incompletely excised lesion does increase the chance of malignancy.

**Mediastinal teratoma:** This is the second most common site for extragonadal germ cell tumors. These tumors may be diagnosed from the fetal period to adolescence. The potential for airway complications makes appropriate management during general anesthesia of paramount importance. These tumors are similarly preferentially treated with complete surgical excision, with biopsy and chemotherapy reserved for tumors that are deemed unresectable.

**Abdominal and Retroperitoneal teratoma:** The most common abdominal teratomas are the gonadal teratomas; however, extragonadal teratomas do occur in the abdomen and retroperitoneum. These tumors are treated similar to other teratomas and may be large or noted to encase major vessels. In these cases, the tumors are biopsied and initially treated with chemotherapy.

Pediatric germ cell tumors are an extremely varied group of neoplasms that necessitate a focused preoperative evaluation and multidisciplinary approach to treatment.

“

**Teratomas that occur in infancy are usually extragonadal, while those occurring in older children and adolescents most often are found in the testis or ovaries.**

”



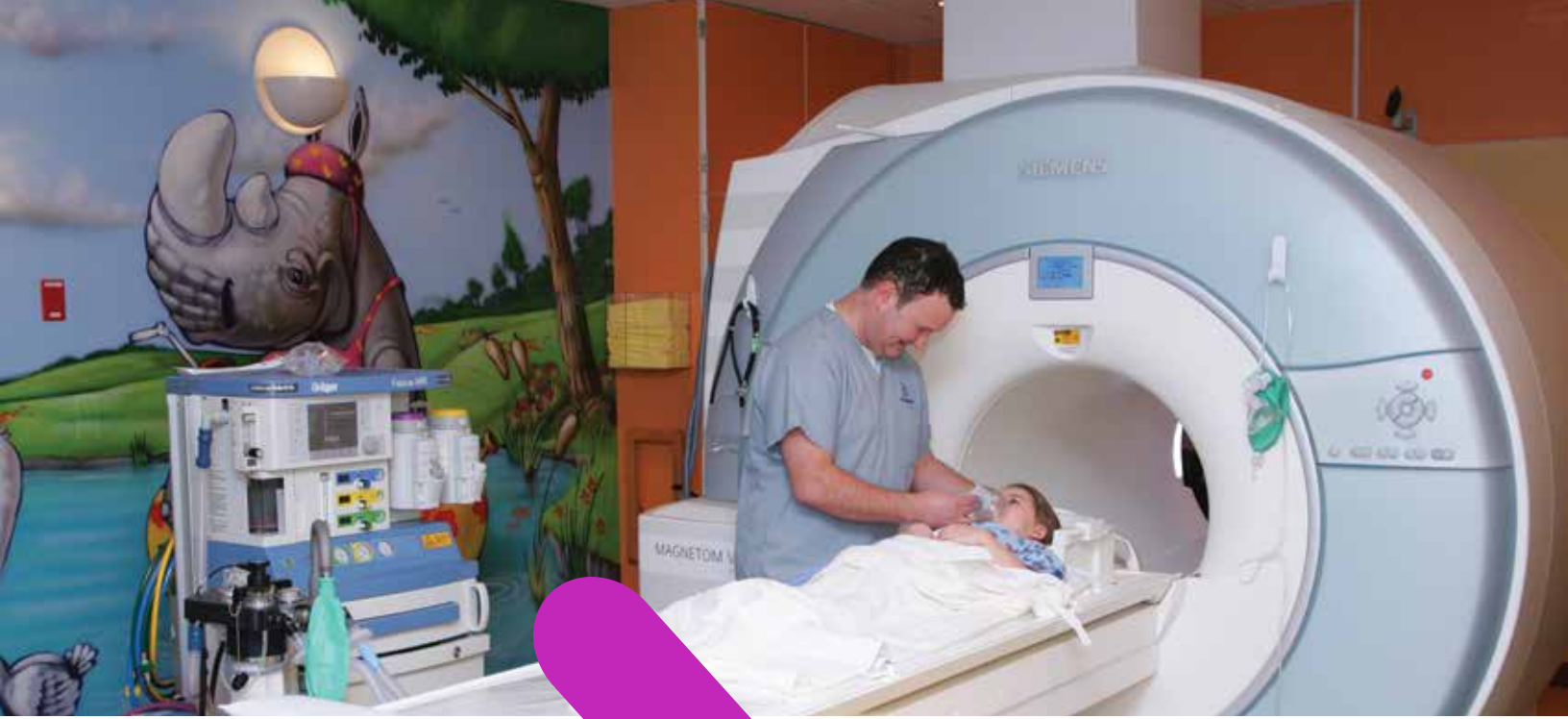# Pathology

Germ cell tumors are neoplasms that arise from the germ cells either located in the gonads or in extra-gonadal locations, such as mediastinum, cranial cavity or the retroperitoneum. Morphologically, these tumors are classified into mature teratoma, immature teratoma, seminoma/dysgerminoma, embryonal carcinoma, yolk sac (or endodermal sinus) tumor, choriocarcinoma and gonadoblastoma. Patients may harbor either a pure, histologically single germ cell tumor or may develop a mixed germ cell tumor, wherein more than one neoplastic cell type is present in the tumor.

To diagnose germ cell tumors, pathologists employ a battery of immunohistochemical stains that identify the neoplastic cells. Some of the typical antigens expressed by the germ cell neoplasms are: AFP in yolk sac tumor, PLAP in seminoma, HCG in choriocarcinoma and CD30 in embryonal carcinoma. However, these markers do not have a very high sensitivity or specificity to be used in isolation. Thus, multiple antibodies are used in a panel to provide an unequivocal diagnosis. Teratomas are an exception for the need to use immunohistochemical stains because this neoplasm has a distinctive appearance on routine hematoxylin-eosin stains.

Serum tumor markers are a valuable tool to aid in the diagnosis and follow-up of patients. Serum levels of alfa-fetoprotein, human choriogonadotrophin, placental-like alkaline phosphatase when significantly elevated prior to the treatment of the neoplasm, can be used to monitor tumor burden or recurrence. Some syndromes such as Trisomy 21 and Klinefelter, undescended testes and streak gonads increase the risk of developing germ cell tumors.





## Radiology

The Diagnostic Radiology department at Children's Mercy is an important part of the care of a child with a germ cell tumor. A variety of imaging studies may be utilized for initial diagnosis, pre-surgical planning and routine surveillance to monitor the tumor's response to therapy.

Though a germ cell tumor may be initially diagnosed with an X-ray or an ultrasound, advanced cross-sectional imaging with computed tomography (CT) or magnetic resonance imaging (MRI) is commonly used to define the tumor and its relationship to adjacent body structures. The addition of new CT scanners throughout the Diagnostic Radiology department allow for faster scan times and decreased radiation dose without sacrificing image quality. Children's Mercy has four MRI scanners, providing state-of-the-art imaging at our Adele Hall, South and East campuses.

As a CT or MRI examination can be a frightening experience, some children may require the care of our sedation nurses or pediatric anesthesiologists. However, creation of a comfortable environment and distraction techniques by our team of imaging experts and Child Life specialists may remove the need for sedation.



# Cytogenetics

Cytogenetics is a laboratory specialty that studies tissues to determine genetic changes that occur in the cells of tumors. Since all cancers have genetic changes and these changes are specific to each tumor, it is important to investigate each child's tumor. Certain genetic changes can help define the tumor type and other genetic changes may help determine the best therapy for treatment.

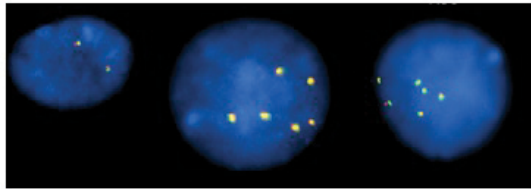
The cytogenetics laboratory uses several methods to investigate. One method grows the tumor cells and then captures the cells when they divide so the chromosomes can be seen. Chromosomes are where the genes reside. Another method uses fluorescent probes to look at specific genes to determine if something has happened to the gene. Several methods use the genetic material, DNA, after it is isolated from the tumor cells. DNA can be used for microarray analysis and various molecular tests. Microarray analysis investigates tumor DNA by looking for changes throughout the genome.

The molecular genetics laboratory uses methods to look deeply into the genes with some methods looking at specific genes and other methods



Linda Cooley, MD

Figure shows fluorescent probe that indicates 6 copies of 12p in two cells and a normal cell with two copies.



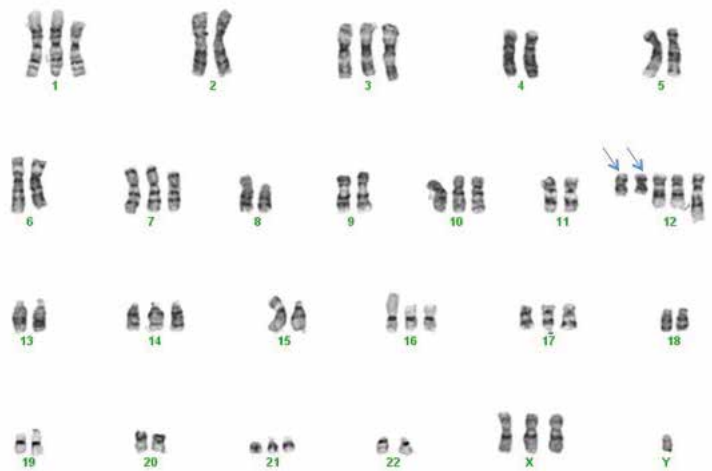
sequencing or “reading” all the genes in the genome. The goal of the studies is to detect mutations or changes specific for the tumor being studied.

Results obtained from these studies provide the oncology team with a genetic picture specific to each child’s tumor. This information is used along with all other laboratory and clinical information in planning for the optimal care of each child.


Specifically, germ cell tumors are a group of rare tumors that can arise in the gonads and at other places in the body. The clinical course and outcome of the various GCTs differ. Tumors can be found from newborn to old age. Testicular GCTs are the most common tumor in males ages 10 to 40. Cryptorchidism is associated with approximately 10 percent of testicular GCTs. Testicular GCTs in infants are rare neoplasms occurring in boys 0–4 years. Ovarian GCTs may occur in patients with gonadal dysgenesis. Rarely, GCTs occur extragonadally in the brain, mediastinal or sacrococcygeal regions. Pediatric mediastinal GCTs have the same histologies as gonadal GCTs, but have a worse prognosis. The mediastinum is a common site in young males and these tumors are associated with Klinefelter syndrome in approximately 20 percent of cases. Sacrococcygeal GCTs, the most common extragonadal GCT in children, present prenatally to approximately 4 years.

GCTs in adults and post-pubertal children are characterized by extra copies of the chromosome 12 short arm (12p), or part of 12p. Other chromosome anomalies occur in this age group, which are different from those found in the GCTs of infants and prepubertal children. Gain of 12p is rarely reported in prepubertal children and infants. Microarray analysis has shown that 12p is affected differently in adult GCTs and GCTs of very young children. GCTs are rare in children between ages 5 and 9 years, thus there is little known about the genetics of tumors from this age range.

Figure shows karyotype with extra copies of chromosome 12 short arm (arrows). Other abnormalities are also present.







# Gynecology

Germ cell tumors of the ovary are relatively common solid neoplasms of children and adolescents that form probably due to abnormal differentiation of fetal germ cells. The risk of developing a germ cell tumor of the ovary increases with age until about the age of 15- 19. Most germ cell tumors of the ovary are benign cystic teratomas with only 1-3 percent having malignant features. Seventy percent of all malignant ovarian tumors are germ cell in origin.

Benign teratomas can form in several areas of the body, with the ovary being the second most common site. These tumors have components deriving from all embryonic layers and developing tissues that are otherwise not seen in the ovary. They may accumulate fluid and contain structures such as hair, teeth and sebaceous material, and on occasion grow to a very large size. This can be associated with replacement of normal ovarian



Julie Strickland, MD

tissue, as well as pain from ovarian torsion (twisting) and cyst rupture.

Often, these tumors are first seen incidentally upon imaging with ultrasound, X-ray or CT scanning with their characteristic findings of calcification and fat present within the cystic ovary. Surgical management of ovarian teratomas is commonly done through minimally invasive surgery with conservation of the ovary involved. The prognosis with this technique is excellent with a less than 10 percent risk of recurrence.

Occasionally, teratomas may have malignant features associated with immature elements. Despite their malignant potential, they have a good prognosis with adequate surgery and close postoperative surveillance. Resection of these tumors, along with careful assessment at the time of surgery and with imaging, is essential as recurrence can be as high as 33 percent. Recurrence risk is related to both the size and completeness of resection. Conservative, fertility sparing surgical treatment of malignant teratomas and other germ cell neoplasms is strongly encouraged. Often, the tumor may secrete markers such as AFP and hCG which allow monitoring for relapse.

Other types of malignant germ cell tumors are rare and can require both surgical removal and chemotherapy. Before current developments in chemotherapy, the 10-year survival rate for malignant germ cell tumors ranged from 25 percent for embryonal carcinoma to 75 percent for dysgerminoma. Today, overall survival rates are greater than 90 percent with fertility sparing conservative surgery and chemotherapy.

At Children's Mercy, pediatric gynecologists and surgeons work closely with oncologists and diagnostic radiologists to treat germ cell tumors of the ovary. Emphasis is placed on fertility.

“

**Before current developments in chemotherapy, the 10-year survival rate for malignant germ cell tumors ranged from 25 percent for embryonal carcinoma to 75 percent for dysgerminoma. Today, overall survival rates are greater than 90 percent with fertility sparing conservative surgery and chemotherapy.**

”



# Urology

Malignant testis tumors are rare in children. The risk for malignant tumors increases after boys go through puberty. In boys, most tumors are benign. In adults, the vast majority are malignant.

The approach to a testicular mass in a boy before puberty is often biased toward a testis-sparing approach. Unless specific lab markers for malignancy are present, the tumor is removed from the testis and if it proves to be a benign lesion, the remaining testis is preserved. Benign tumors require no further therapy after surgery.

In boys after puberty, these lesions are most commonly malignant and the entire testicle is removed. In this setting, work is undertaken to see if the tumor has spread.

The mainstay of therapy for malignant tumors is chemotherapy. Sometimes radiation is used. If the tumor has spread to the abdominal lymph nodes and does not disappear with this therapy, they may require surgery.



John Gatti, MD



Overall cure rates for testicular cancer are greater than 90 percent. The common tumors we consider are very different in pre-pubertal boys compared to post-pubertal boys, and boys progressing through puberty at the time of diagnosis present a unique challenge because the tumor may exhibit the behavior of either group.

At Children’s Mercy, we have a close relationship with our adult urology colleagues at the University of Kansas and maintain a role as teaching faculty at both institutions. If an abdominal operation to remove lymph nodes is required, these children are often referred to KU.

### **Screening for Testis Tumors**

As boys enter puberty, heralded by the growth of underarm and pubic hair growth, they are at increasing risk for testicular malignancy. These most commonly tend to occur from the age of 15 to 40 years. The risk is higher in boys with a history of having an undescended testis. Testis tumors may also be more common with some genetic syndromes or a significant family history.

Once puberty begins, we recommend that boys begin performing testicular self-examination to become familiar with the shape and consistency of the testes and to identify any suspicious masses. These tend to be hard, painless lumps in or on the testis itself. If a mass is found, medical evaluation is warranted.

“

**The approach to a testicular mass in a boy before puberty is often biased toward a testis-sparing approach.**

”



## Genomics and Biorepository

The Children's Mercy Cancer Genomics Program is the work of the Children's Mercy Cancer Center and the Center for Pediatric Genomic Medicine. The program makes next-generation sequencing research available to all oncology patients. Any child, adolescent, or young adult who is treated for a germ cell tumor at Children's Mercy may enroll in a research protocol for genomic sequencing. Once enrolled, DNA from the patient's healthy blood cells and DNA from the patient's tumor cells are analyzed and compared. The result is a detailed report of the tumor's biology, which can help researchers better understand the causes of germ cell tumors. In some cases, genomic sequencing may help clinicians choose treatments that are targeted to each patient's tumor.

Beginning in 2016, part of the support for the Cancer Genomics Program and other research programs, will be the Cancer Center Biorepository. Patients with germ cell tumors may opt to donate blood, leftover tumor samples, DNA and clinical data to the Biorepository. The donated material and clinical data are stored in a protected database and are available to research scientists with approved protocols to study cancer and related diseases. By participating in the Biorepository, patients with germ cell tumors provide a critical resource needed to make progress toward targeted treatments and even better cure rates.



Erin Guest, MD



Joy Bartholomew, APRN



## Advanced Practice Nurses

Advanced Practice Nurses are a part of the care team for patients with germ cell tumors. APNs are master's or doctoral-prepared nurses who partner with the patient's physician to provide individualized care. This approach allows for consistent providers for the patient and family. APNs provide case management services for patients' total therapy needs. Patients with germ cell tumors often require specific labs, chemotherapy, radiology imaging, inpatient and outpatient treatments, and home care. All of these needs are well coordinated by the APN. The APN provides education throughout the process. The APN reviews the therapy and how it is affecting the patient, performs physical examinations, orders laboratory tests and scans, and prescribes medications. The APN is the point person for phone contact when families are home. Children's Mercy also has APNs that manage the inpatient chemotherapy service. They see the patients in the morning, do physical exams, adjust medications and round with a physician each day. They are able to provide continuity of care for these patients who are frequently hospitalized.





## FaCT Team

Outside of medically directed care, patients and families have many other needs addressed by our Family Care Team (FaCT). Regular FaCT rounds and collaboration ensure that physical, developmental, emotional, educational and spiritual needs are met for our patients and families. The Family Care Team is available to assist from point of diagnosis through the completion of treatment and beyond.

**Child Life Specialists** promote a positive environment for patients and families. This is accomplished by providing materials and guidance for developmentally appropriate play, preparing children for medical experiences, advocating for patient and family rights, and promoting a non-threatening environment. Our team tries to reduce stress and worry. We help children deal with their feelings, thoughts and questions. We provide services to help children continue to learn and grow while in the hospital.

**Clinical Social Workers** are licensed professionals working as part of the primary team. The social worker understands that any change in the child's

Stephanie Easley, CCLS,  
Child Life




Liesel Stephens, MT-BC,  
Music Therapy

health can alter a family's life in many ways and they are trained to provide a thorough assessment and address the needs of the patients and families. Social workers can help with adjustment to illness, crisis intervention, development of coping skills, family concerns, advanced directives, end of life, bereavement, school concerns, legal issues, transition to adult care and community/resource referrals to assist with financial concerns, transportation and lodging needs, support and mental health.

**The Parent to Parent Program** offers support and comfort to all families through the Parent Rooms, Peer Match Program, and bereavement follow-up. Among the services offered are: trained parent mentors available to share, listen, and support current parents; two stocked parent rooms that offer weekly dinners, breakfasts, therapeutic and educational activities and a safe place to unwind while a child is an inpatient; and "care bags" for new families upon admission to help ease some burden of a hospital stay. The Parent to Parent program also offers an extensive bereavement follow-up program (including social media) that supports families after a child's death.

The Hematology/Oncology Division has two **psychologists** to assist patients and families with coping with the diagnosis and treatment of germ cell tumors and other cancers. They are available to meet with patients and their families both while hospitalized and when an outpatient. In addition to therapy services, the psychologists are also able to complete neurocognitive evaluations to assess any impact of medical treatment on brain functioning and to assist with school re-integration and planning.

The **Chaplain** working with Hematology/Oncology/BMT is available to meet and provide spiritual and emotional support for patients and families during the course of the child's illness, as end-of-life discussions are necessary, at the time of death and beyond. The chaplain can assist in contacting a



Amanda Trout, LMSW, LCSW  
Social Work

family's own clergy if requested, or locating a local clergy of the patient/family's denomination or faith for families who are not from the area. The chaplain also provides education on spiritual resources and support available within the hospital including the chapel, worship opportunities and special events. Additionally, the chaplain provides support to members of the staff.

**Music Therapy** services are offered to patients and families at bedside to address the specific needs of each individual patient. Music interventions are designed after an assessment of need, and generally involve the use of both live vocal and instrumental music. Goals may include (but are not limited to) the reduction of pain or anxiety; increased self-expression, movement, or relaxation; and the support of developmental skills.

An on-site **school teacher** works with patients primarily on the inpatient floor with some availability in clinic as needed to assist with the challenge of keeping up with school work. Our school teacher is able to communicate directly with the child's school to get current assignments and also to advocate for the patient's needs once they return to the school setting.





## Survive & Thrive

The Survive & Thrive Program offers comprehensive medical and emotional care to childhood cancer survivors who are at least two years off treatment and five years from the date of diagnosis. Survivors are at risk for late effects from their cancer and treatment. Late effects of treatment can be physical or emotional and typically appear at ages 10-20. The development of late effects may be influenced by the type of cancer, the treatment, age at diagnosis and genetic predisposition. An estimated 75 percent of childhood cancer survivors will develop at least one late effect at some point during their life. Late effects may be preventable or modifiable, which is why yearly lifelong follow-up is important for all survivors.

Examples of late effects that may occur in survivors with a history of germ cell tumor include hearing loss, lung dysfunction, and development of a second cancer. In the Survive & Thrive Clinic, survivors are monitored for development of late effects based on the treatment they received and according to the Children's Oncology Group Long-term Follow-up Guidelines. The team ensures any recommended testing is performed and monitors those results. The Survive & Thrive team works closely with health care providers in other specialties to ensure each survivor's unique health needs are met.

A visit to the Survive & Thrive Clinic includes a thorough physical exam, recommendations for long-term follow-up care, education on late effects and recommendations for maintaining a healthy lifestyle. Included in the visit are nutritional and psychosocial assessments. As survivors reach the teenage years, preparation for transition to adult providers is incorporated into each visit. The Survive & Thrive team works with each survivor to help them learn how to advocate for their health care needs once they leave the pediatric setting.





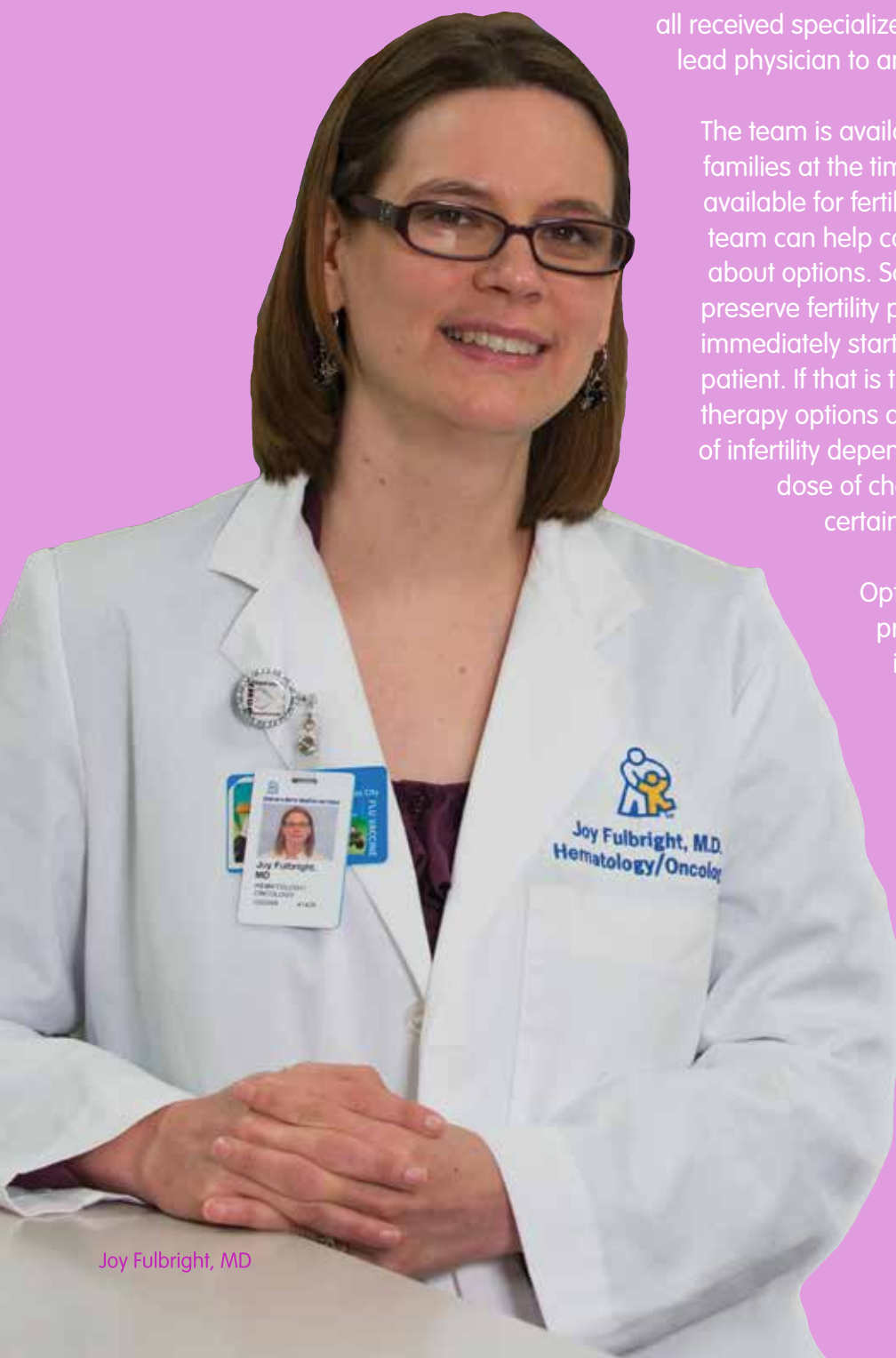
# Fertility Preservation at Children's Mercy

With increased survival of pediatric cancer patients, there comes more focus on quality of life post-treatment. Cancer treatment may affect the survivor's fertility. A fertility preservation team has begun work to explore this unfortunate side effect. The team consists of a social worker to help address the financial concerns, nurse practitioners who have all received specialized training in fertility preservation, and a lead physician to answer medical questions.

The team is available to meet with patients and their families at the time of diagnosis to review options available for fertility preservation prior to treatment. The team can help coordinate services and answer questions about options. Sometimes, patients are not able to preserve fertility prior to treatment due to the need to immediately start therapy or age/maturity level of the patient. If that is the case, the team can help discuss post-therapy options and the risk of treatment. A patient's risk of infertility depends on multiple factors, including type/dose of chemotherapy, radiation location/dose and certain types of surgery.

Options that are available for fertility preservation in the Kansas City area include sperm cryopreservation, egg harvesting/cryopreservation or embryo cryopreservation. After cancer treatment, many of our survivors will recover fertility, but for those that do not, options include in vitro fertilization with donor egg/sperm, surrogacy, embryo adoption, international or domestic adoption or adoption through the foster care system.

For more information regarding this service please contact Joy Fulbright, MD, at (816) 302-6808.



Joy Fulbright, MD



# Canines Hunter and Hope Join Children's Mercy Staff

Children's Mercy recently welcomed two golden retrievers to the staff.

Hunter and Hope are on the job at the Adele Hall Campus and Children's Mercy Hospital Kansas (respectively), delivering comfort, cheer and day-brightening tail wags to help patients on their road to recovery. Hunter is stationed in the Hematology/Oncology area, working with patients with cancer; Hope works in the Comprehensive Epilepsy Center.

With Hunter's and Hope's presence, lives of Children's Mercy patients are being changed for the better.

"We've had dogs here at Children's Mercy for years, primarily through 'Pet Pals,' a program where volunteers bring their dogs to the hospital on Thursday evenings for a group session," said Missy Stover, Child Life Volunteer and Therapeutic Programs Manager and Manager of the Facility Dog Program. "We also have dogs in our Rehabilitation Unit on Wednesdays to help kids meet their therapy goals. But we've always thought how wonderful it would be if we could have a dog here every day. It's been a dream of mine."

Now that dream is a reality.



Hunter



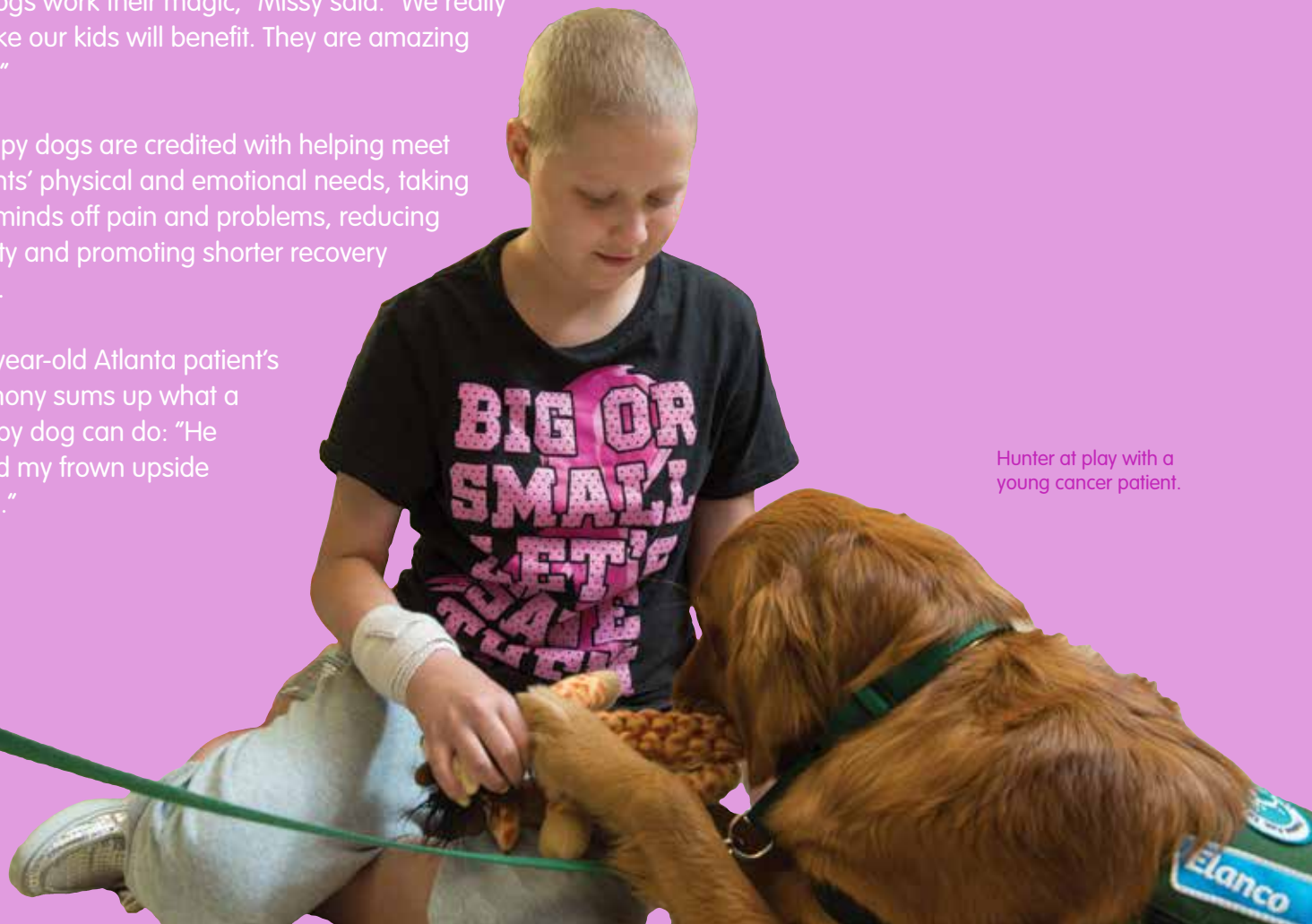Hunter with handler, Aimee Hoflander and Hope with handler, Allison Bowring, from our Child Life Facility Dog Program.

Both dogs were trained at Canine Assistants, an Atlanta organization that provides service dogs to individuals and facility dogs to pediatric hospitals across the country.

"We got to go to the hospital (in Atlanta) and see the dogs work their magic," Missy said. "We really feel like our kids will benefit. They are amazing dogs."


Therapy dogs are credited with helping meet patients' physical and emotional needs, taking their minds off pain and problems, reducing anxiety and promoting shorter recovery times.

A 10-year-old Atlanta patient's testimony sums up what a therapy dog can do: "He turned my frown upside down."



Hunter at play with a young cancer patient.





## Annual Report Contributors

Maxine Hetherington, MD - Editor

Atif Ahmed, MD

Joy Bartholomew, APRN

Cathy Burks, RN, APRN

Linda Cooley, MD

Brian Dunoski, MD

Joy Fulbright, MD

John Gatti, MD

Erin Guest, MD

Wendy McClellan, RN, CPNP

Evan Nelson

Lisa Peters, LMSW, LCSW

Robin Ryan, MPH, CCRP

Sohail Shah, MD

Vivekanand Singh, MD

Julie Strickland, MD, MPH

Cindy Thompson, CTR







**Children's Mercy**  
**KANSAS CITY**

2401 Gillham Road  
Kansas City, MO 64108  
(816) 234-3000  
[childrensmercy.org/cancer](http://childrensmercy.org/cancer)

