Lower Extremity Fracture Case Presentations

Children's Mercy

Kansas City, MO

Case 1

- 13 y 7 mo old female running at gym class and felt sudden pain in her left leg, after which she fell and could not walk

- No previous notable medical history. No previous pain in left leg

- Is in 8th grade. Has a passion for the piano. Does not participate in organized sports. Lives 4 hours away from hospital.

Children's Mercy
KANSAS CITY

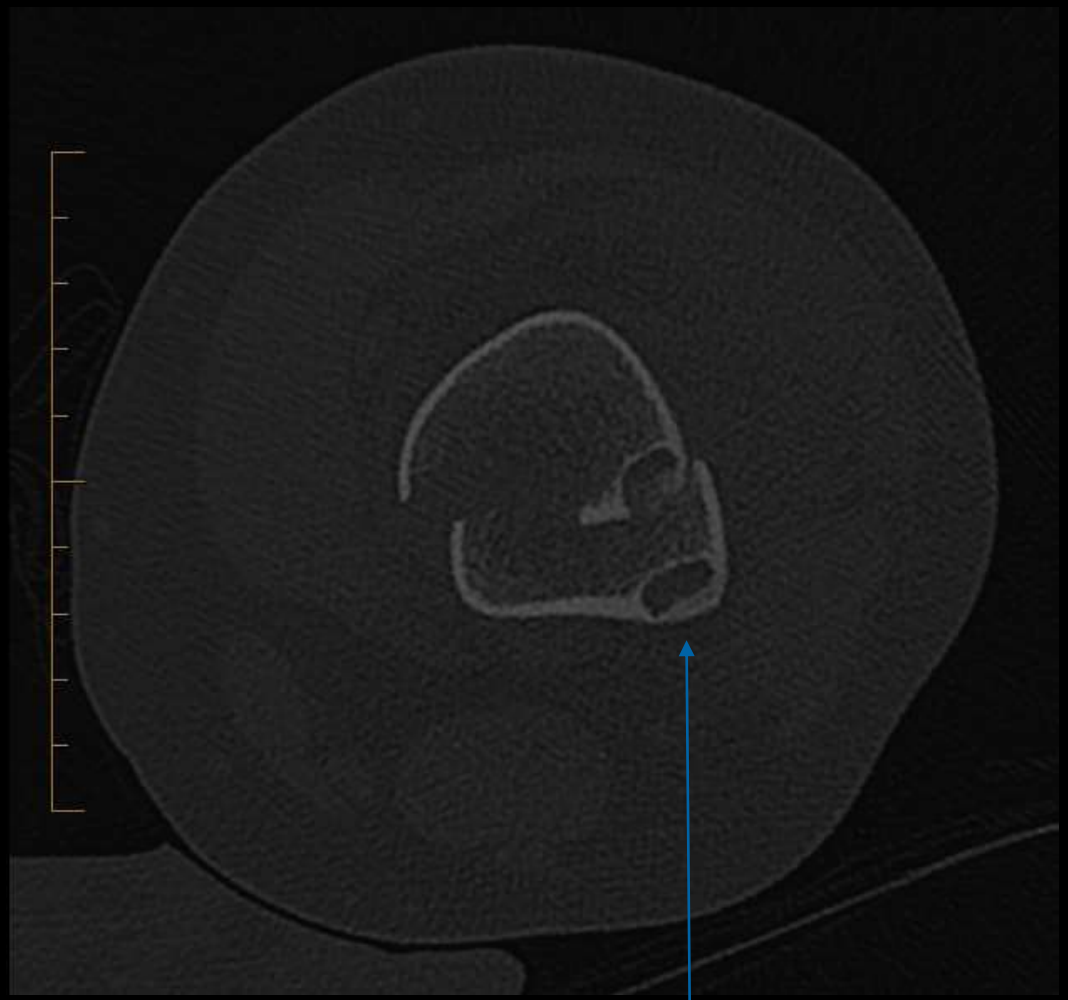

Fibrous cortical defect

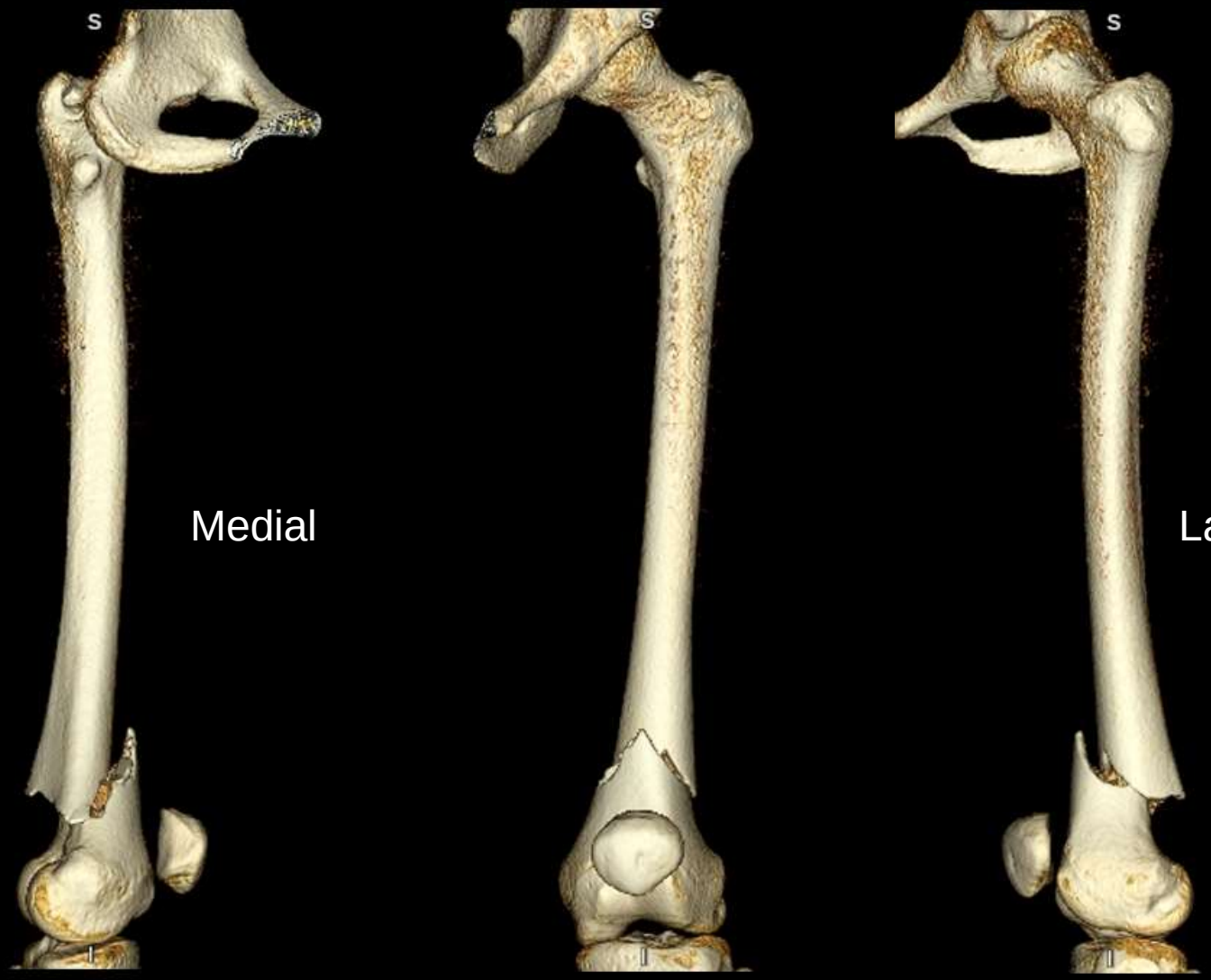

Open reduction (closed reduction unsuccessful) of distal femur fracture with retrograde nailing and proximal and distal locking screws

Treated in a knee extension brace and TTWB allowed

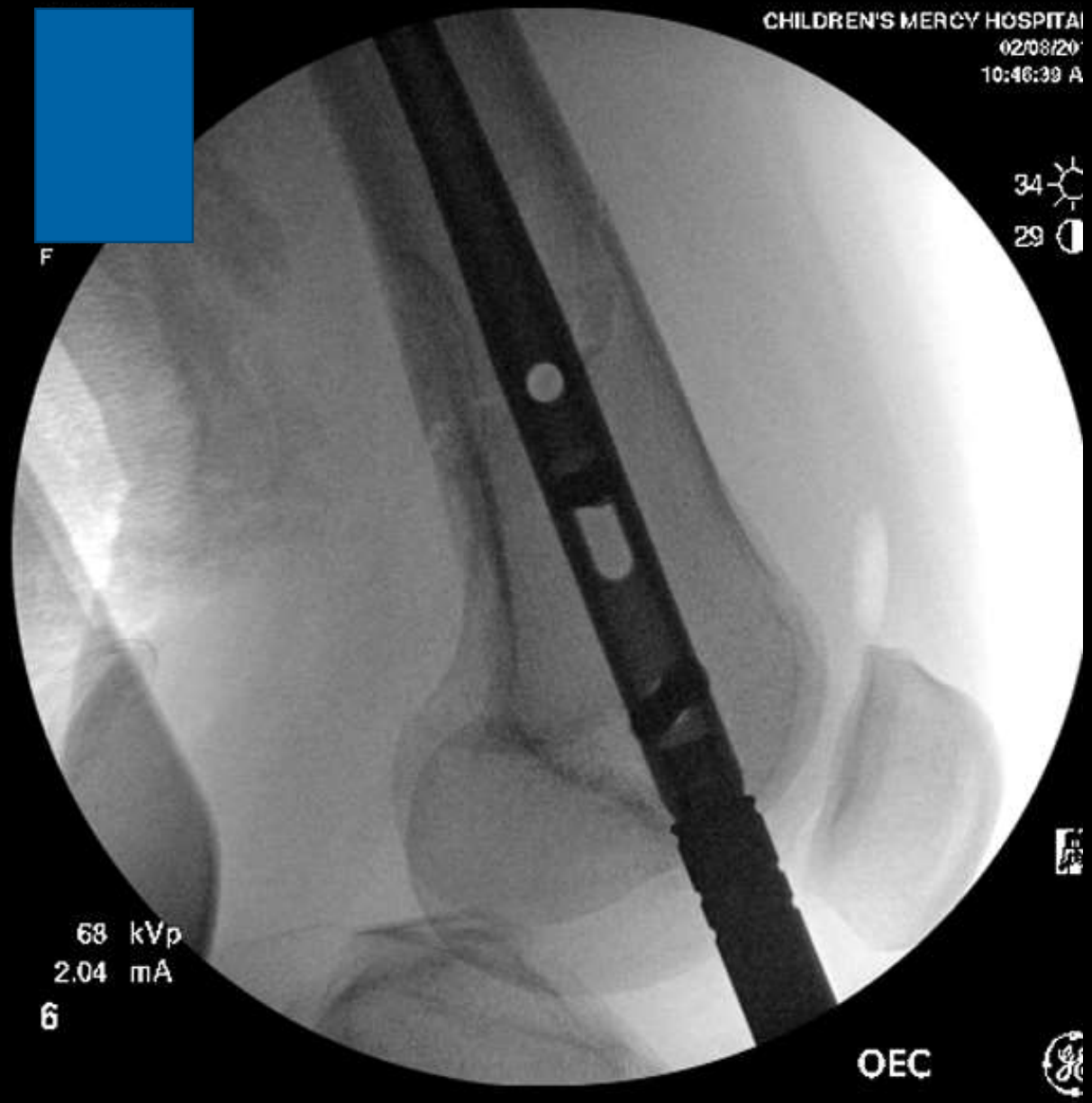

Children's Mercy
KANSAS CITY

6 weeks post injury

Having no pain and neither the patient nor the parents notice any clinical deformity

Allowed to start weightbearing at this time

Children's Mercy
KANSAS CITY

6 months post op

Has returned to full activities (can run to the piano!)

No pain, and no perceived deformity

Initial post op: aLDF angle= 80.2 degrees

6 month post op: aLDF angle= 88.3 degrees

Children's Mercy
KANSAS CITY

Supracondylar nail with more distal and multidirectional screws may limit this problem



Case 2

- 16 y o previously healthy male running cross country and sprinting to finish when his left leg gave out
- No history of previous pain in thigh or knee

Immediate post –op xrays

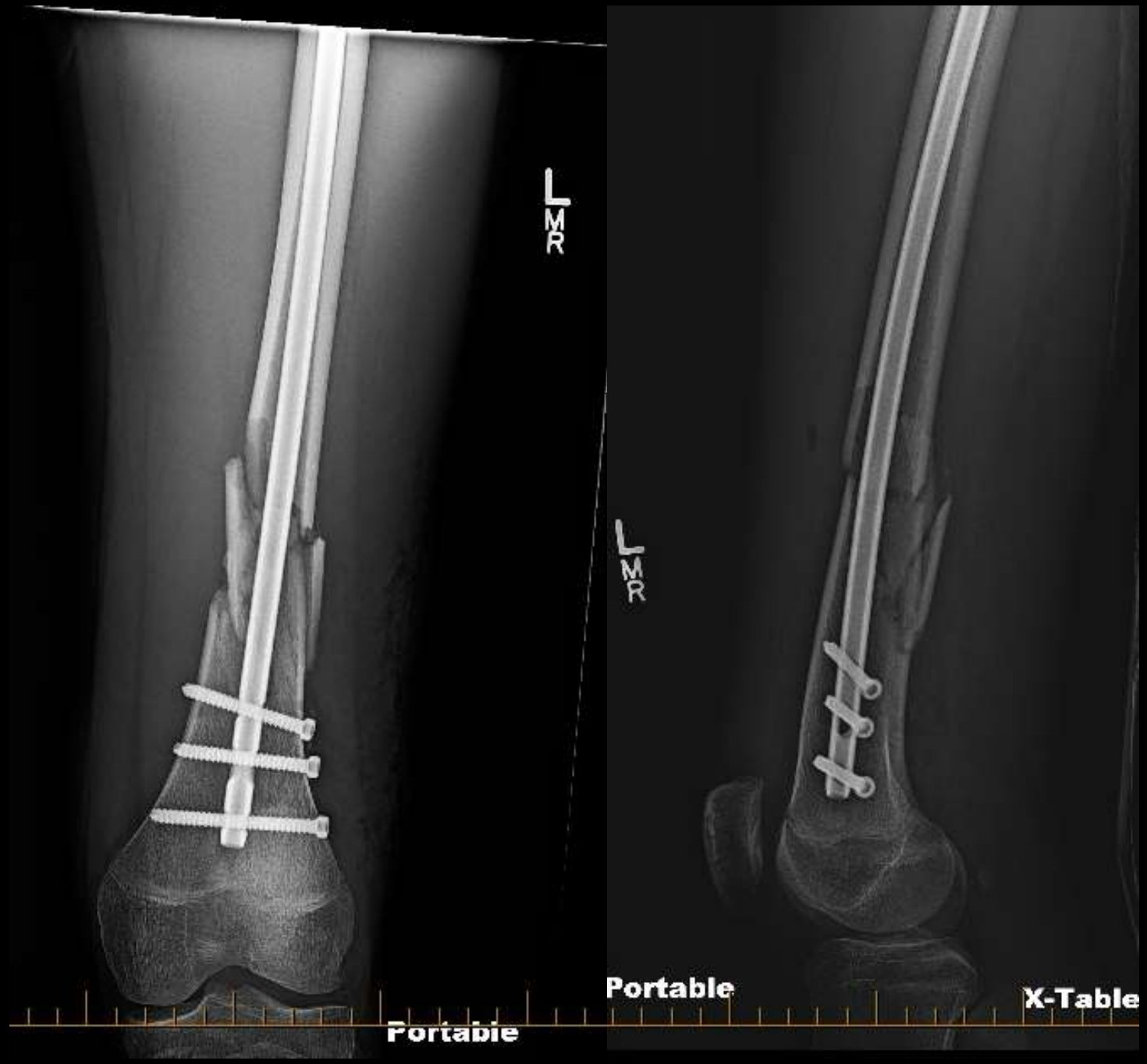

Children's Mercy
KANSAS CITY

2 weeks
post op

Case 3

2 year and 9 month old at trampoline park with family while visiting friends in Dallas, Texas

Was standing on a trampoline pad when Dad accidentally stepped on it, sending child sprawling

Child refused to bear weight after the incident

Was seen in an urgent care where these radiographs were obtained

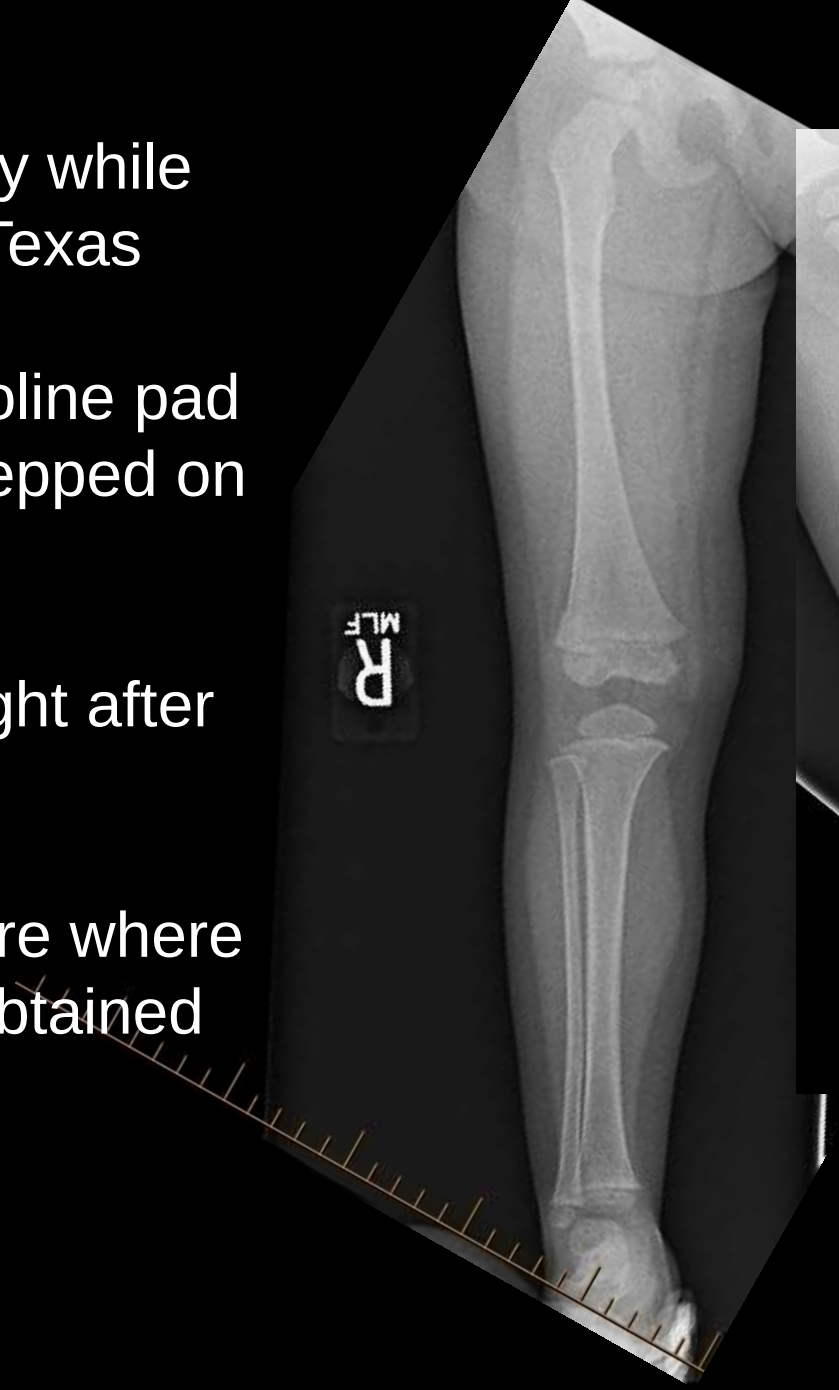

DOI: 8/3/2017

Children's Mercy
KANSAS CITY

- Was placed in a posterior splint at urgent care in Dallas and referred to orthopaedics for follow up
- Presented to ortho clinic in Kansas City 5 days post injury
- At that time, her leg was comfortable in the splint. She was complaining mostly of heel pain

- Placed in a cylinder cast (thigh to ankle) and local wound care provided for heel

8/8/2017

4 weeks post injury

- Cast removed and child allowed to weight bear as tolerated
- Continued local wound care with dry gauze and self-adherent wrap

9/8/2017

- Six weeks post injury, child is now walking without a limp
- Still using dry gauze and self adherent wrap and using regular shoe
- Periphery of heel eschar debrided, but central area still healing underneath

9/14/2017

- 10 days later, complains of increasing pain and swelling
- Treated for cellulitis with oral cephalexin for 5 days with resolution of symptoms

9/27/2017

- 2 months post injury
- Child now walking and running without a limp
- Eschar starting to lift off
- Underwent office debridement

10/5/2017

Children's Mercy KANSAS CITY

Eleven weeks post injury

Children's Mercy
KANSAS CITY

Case 4

13 y 2 mo old female fell on a trampoline and sustained a closed tibia and fibula shaft fracture

Otherwise healthy, active, and not an aspiring Olympian

Started her menstrual cycles regularly 6 months prior to this injury

Immediate post reduction xrays

Children's Mercy
KANSAS CITY

f/u one week later, cast has been subsequently bivalved

Underwent flexible nailing of her fracture 10 days post injury. Films 1 month post op

Children's Mercy
KANSAS CITY

4 months post op

Children's Mercy
KANSAS CITY

1 year post op

Children's Mercy
KANSAS CITY

Operative Versus Conservative Management of Closed Displaced Tibial Shaft Fractures in Adolescents

Kinney MC, Nagle D. et al. J Pediatr Orthop. 2016;36:661-666

- Retrospective review of all adolescents (ages 12-18) presenting to one of two Level I trauma centers with a diaphyseal tibia fracture over an 8 year timespan
- 74 patients met inclusion criteria (approx. 9/year). Surgeon preference whether treated with closed reduction and casting (CRC) or intramedullary nailing (IMN)
  - 57 (77%) initially treated with CRC
  - 17 (23%) initially treated with IMN. Demographic data showed this group was older, had higher energy injuries, and had more associated injuries.

Operative Versus Conservative Management of Closed Displaced Tibial Shaft Fractures in Adolescents

Kinney MC, Nagle D. et al. J Pediatr Orthop. 2016;36:661-666

- Of the 57 treated with initial CRC, only 34 (60%) were treated to completion with that treatment
- 23 (40%) of the initial CRC patients were subsequently converted to IMN due to “unacceptable reduction”
- Findings most likely to lead to a failure of CRC were:
  - Presence of a fibula fracture
  - Initial sagittal plane displacement of greater than 20%

Case 5

- 14 y 7 mo old male *playing basketball in the park when somebody just started shooting*
- He sustained one bullet wound to his left thigh
- BP 124/79 HR 110 upon arrival to trauma bay
- Left lower extremity motor and sensory exam normal
- Left foot with good cap refill but slightly cooler to touch when compared to the right
- Pulses palpable and dopplerable, but asymmetric when compared to normal right side

* History given by patient may or may not reflect the true events surrounding the injury*

- 14 y 7 mo old male playing basketball in the park when somebody just started shooting
- He sustained one bullet wound to his left thigh
- BP 124/79 HR 110 upon arrival to trauma bay
- Left lower extremity motor and sensory exam normal
- Left foot with good cap refill but slightly cooler to touch when compared to the right
- Pulses palpable and dopplerable, but asymmetric when compared to normal right side
- Doppler arterial pressure index 0.8 when comparing normal right leg to injured left

- Patient given antibiotics for open fracture
- CT Arteriogram then performed to evaluate blood flow to extremity
- CT also used to evaluate fracture pattern to plan operative fixation

Bullet/bone fragments partially occluding femoral artery

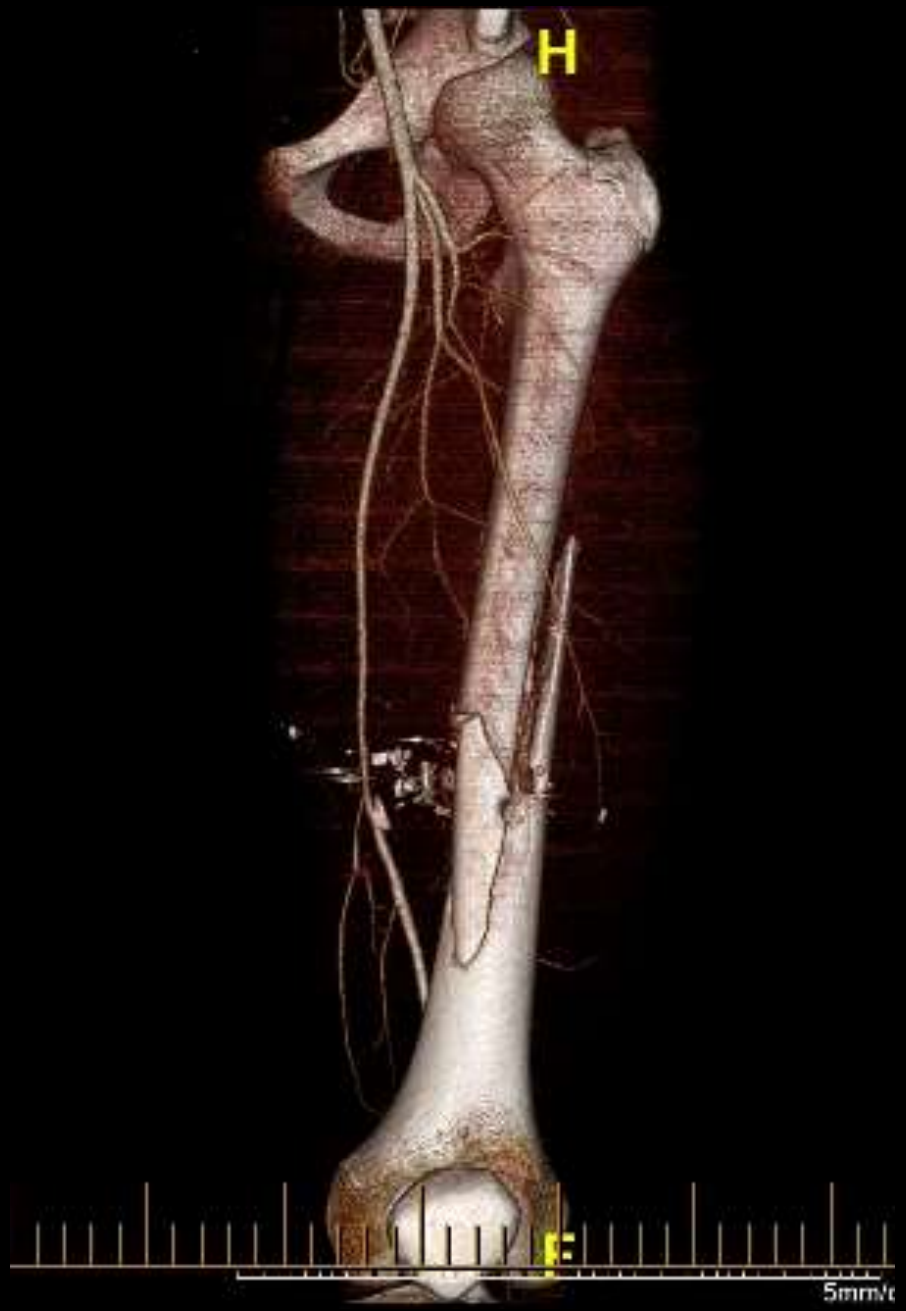

Anterior View

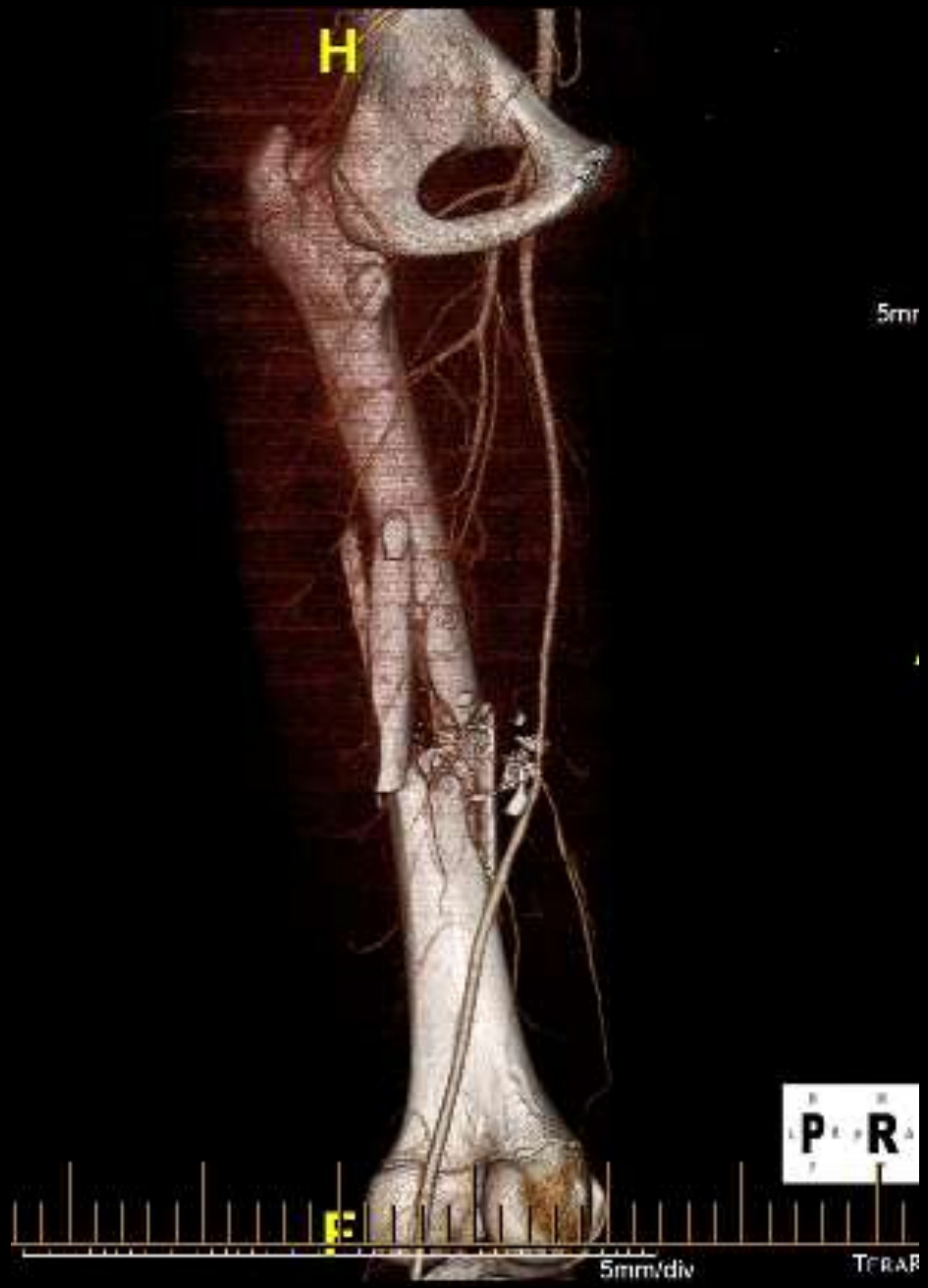

Posterior View

Children's Mercy
KANSAS CITY

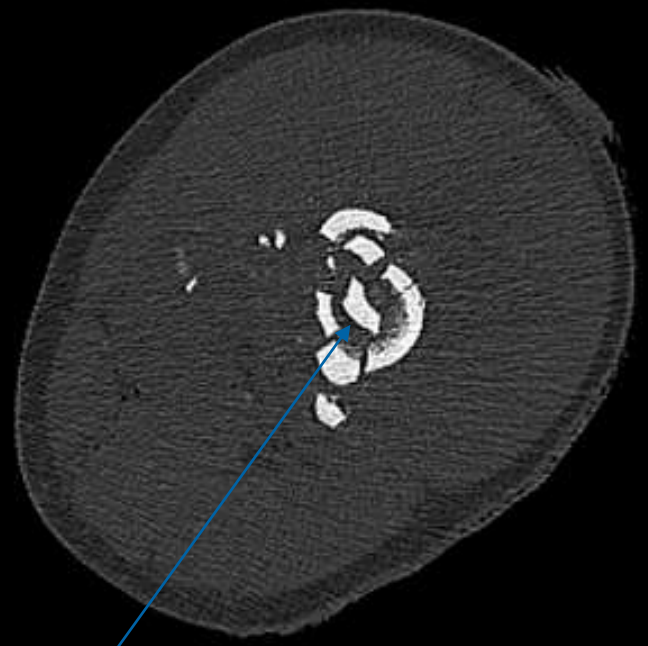

Incarcerated fragment
in femoral canal

Doppler arterial pressure index = 1.0 at end of case

Bullet wounds left open to heal secondarily.

Discharged home after antibiotics completed. Instructed to be TTWB only and set up for outpatient physical therapy

- Lost to follow up for a few months
- Returned 4 months post op with bullet wounds healed and walking without external aids
- Lacked last 20 degrees of knee flexion, but full extension, and a warm foot with easily palpable pulses symmetric to the contralateral side
- Went on to solid bony union at 6 month follow up

Children's Mercy
KANSAS CITY

References

- Tosti R, Rehman S. Surgical Management Principles of Gunshot-Related Fractures. Orthop Clin N Am 2013;44:529-540.
- Eber GB, Annest JL, et al. Non-fatal and Fatal Firearm-Related Injuries Among Children Aged 14 years and Younger: United States, 1993-2000. Pediatrics 2004;113:1686-1692.
- Fowler KA, Dahlberg LL, et al. Childhood Firearm Injuries in the United States. Pediatrics 2017;140:1-11.
- Carter C, Sharkey M, Fishman, F. Firearm-related Musculoskeletal Injuries in Children and Adolescents. J Am Assoc Orthop Surg 2017;25:169-178.
- Abghari M, Monroy A, et al. Outcomes Following Low Energy Civilian Gunshot Wound Trauma to the Lower Extremities: Results of a Standard Protocol at an Urban Trauma Center. Iowa Orthopaedic Journal 2015;35:65-69.
- Senger C, Keijzer R, et al. pediatric Firearm Injuries: A 10 year Single Center Experience of 194 Patients. J Pediatr Surg 2011;46:927-932.

Case 6

- 18 month old female presents with gait abnormality and mild developmental delays
- Not a breech presentation
- No family history of DDH

- Underwent bilateral open reductions with bilateral proximal femoral shortening and derotation osteotomies and bilateral Pemberton acetabuloplasties
- 2.7 mm Synthes mini-fragment plates were used for the femoral fixation

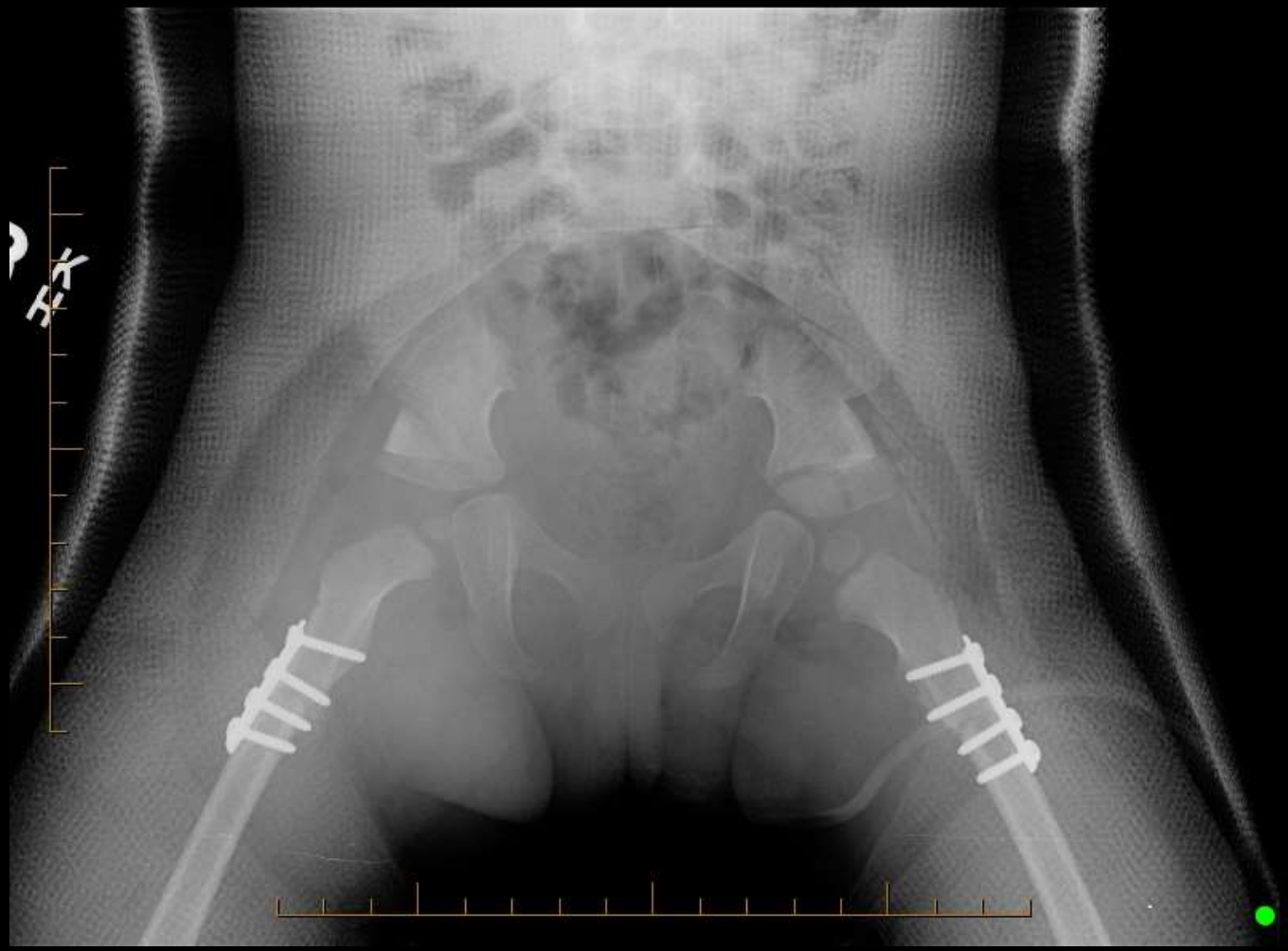

20 months of age

- She is ambulating and has good hip motion at six months post op
- Did require a manipulation under anesthesia 4 months post op to improve range of motion of hips

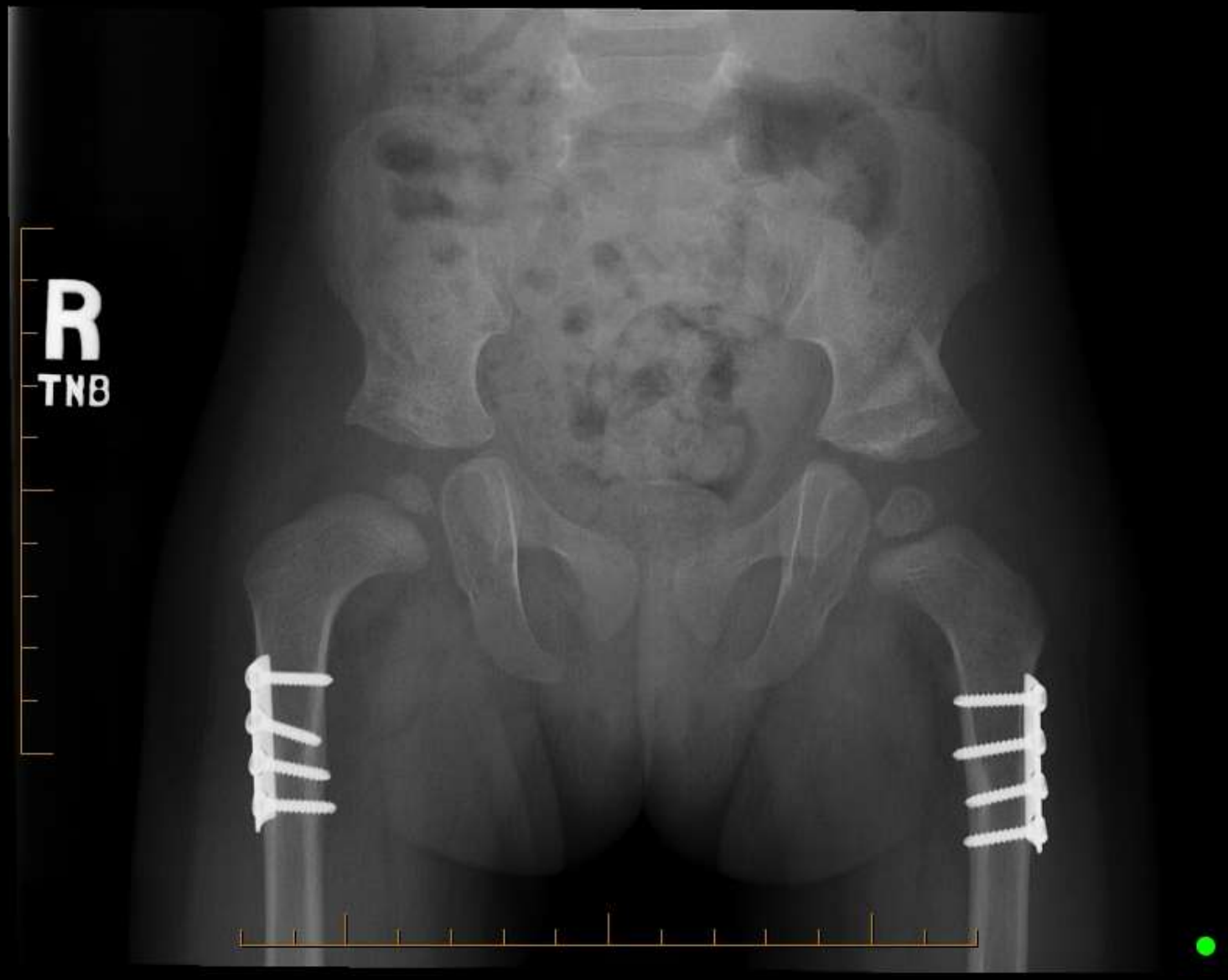

26 months of age

Children's Mercy
KANSAS CITY

- Now over 7 years post surgery
- Walking without a limp
- Participating in regular childhood activities without any symptoms
- Concern about increasing proximal femoral valgus on the right

9 years of age

- 6 months later, tripped and fell over a flip flop while shopping with her mother and sustained a right femoral shaft fracture

9 years 6 months of age

Children's Mercy KANSAS CITY

Undergoes removal of the retained implant, reaming of the proximal femoral canal at the fracture site, and insertion of two retrograde 1.5 mm flexible titanium nails.

One year post-op

Children's Mercy
KANSAS CITY

Flexible nails removed from
right femur 16 months post op

Plate left in on left side as she was asymptomatic

11 years of age

Running in gym class and tripped, falling directly on her left knee.

Sustained left femoral shaft fracture

12 years of age

Children's Mercy
KANSAS CITY

Underwent removal of the femoral implant, reaming of the proximal femoral canal through the fracture site, and subsequent antegrade reamed femoral nailing

Initially an 8 mm diameter implant was utilized, but after difficulty with the proximal locking screws, the femoral canal was reamed up to 10.5 mm and a 9mm X 380 mm locked femoral nail was inserted

Xrays 10 days post op

Children's Mercy
KANSAS CITY

Case 7

8 y 9 mo old female who fell jumping over a mud puddle

Otherwise healthy

Main interest outside of school is racing sprint cars (a family passion)



8 y o sprint car racer

Underwent intramedullary nailing with two 3.0 mm titanium flexible nails

Due to potential for varus angulation, she was placed in a single leg hip spica cast post op

Six weeks post op, at the time of spica cast removal

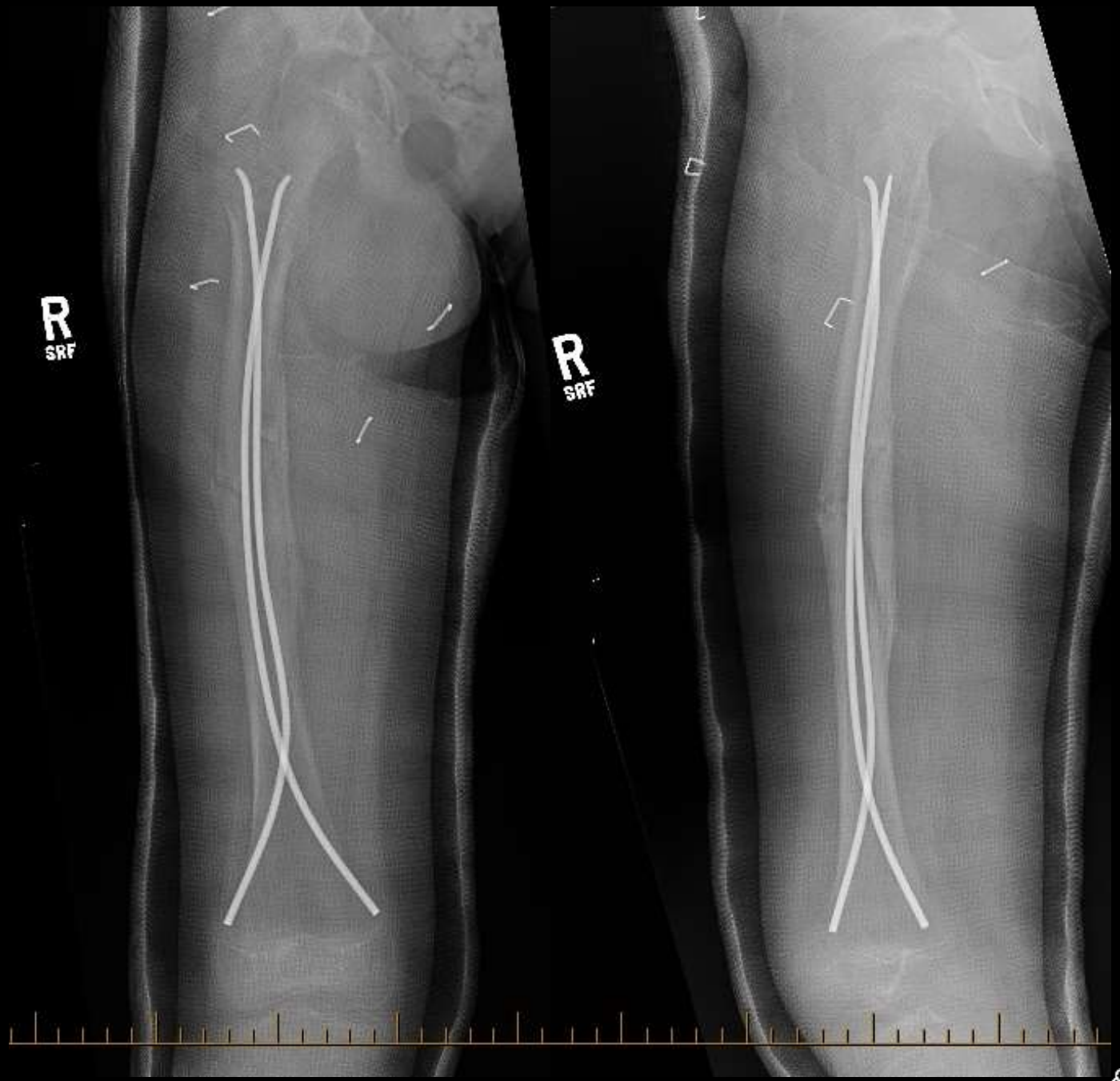

5 months post op

Complains of intermittent thigh pain and still runs with a limp

Is back to sprint car racing!

10 months post op

Seen back for pre-operative assessment for flexible nail removal

Walking and running without a limp, but still complaining of intermittent thigh pain in the area of the fracture

10 months post op

Seen back for pre-operative assessment for flexible nail removal

Walking and running without a limb, but still complaining of intermittent thigh pain in the area of the fracture

Surgery postponed for 6 months

16 months post op

Returns for repeat pre op appointment for flexible nail removal

Leg lengths symmetric

Still complains of intermittent thigh pain

Some pain with palpation over the lateral aspect of the midshaft of the femur

Failed bone marrow injection to treat non-union

Eventually underwent removal of flexible nails and insertion of trochanteric entry femoral nail with subsequent resolution of non union and symptoms

Case 8

4 y 8 mo old male involved in high speed motor vehicle accident

Sustained Grade 3 splenic laceration and right midshaft femur fracture

Fracture splinted for 48 hours while splenic injury observed

When condition stabilized, was taken to OR for evaluation of his femur fracture

Organ Injury Scaling

Spleen

Grade	Injury Description		AIS-90
I	Hematoma	Subcapsular, <10% surface area	2
	Laceration	Capsular tear, <1cm parenchymal depth	2
III	Hematoma	Subcapsular, 10-50% surface area	
		Intraparenchymal, <5cm diameter	2
	Laceration	1-3cm parenchymal depth not involving a parenchymal vessel	2
III	Hematoma	Subcapsular, >50% surface area or expanding.	
		Ruptured subcapsular or parenchymal hematoma.	
		Intraparencymal hematoma >5cm	3
	Laceration	>3cm parenchymal depth or involving trabecular vessels	3
IV	Laceration	Laceration of segmental or hilar vessels producing major devascularization (>25% of spleen)	4
V	Laceration	Completely shattered spleen	5
	Vascular	Hilar vascular injury which devascularized spleen	5

Source: trauma.org

Advance one grade for multiple injuries to same organ up to Grade III.

Children's Mercy KANSAS CITY

Push-pull telescope test showed >3 cm of shortening, so operative intervention chosen over immediate spica casting

Patient was too small to fit on fracture table for traction, so external fixator assisted flexible nailing was performed

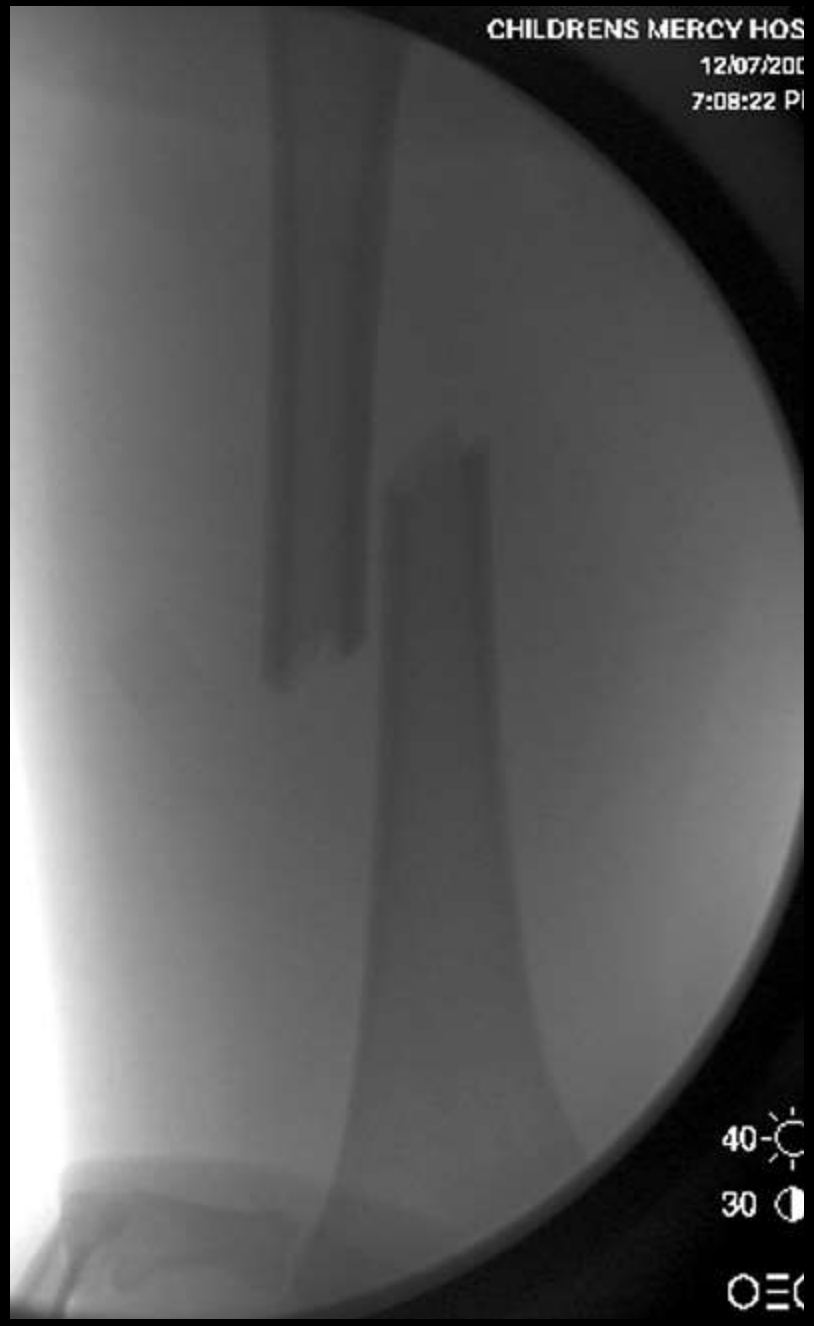

Children's Mercy
KANSAS CITY

Two 3.0 mm flexible titanium nails were utilized

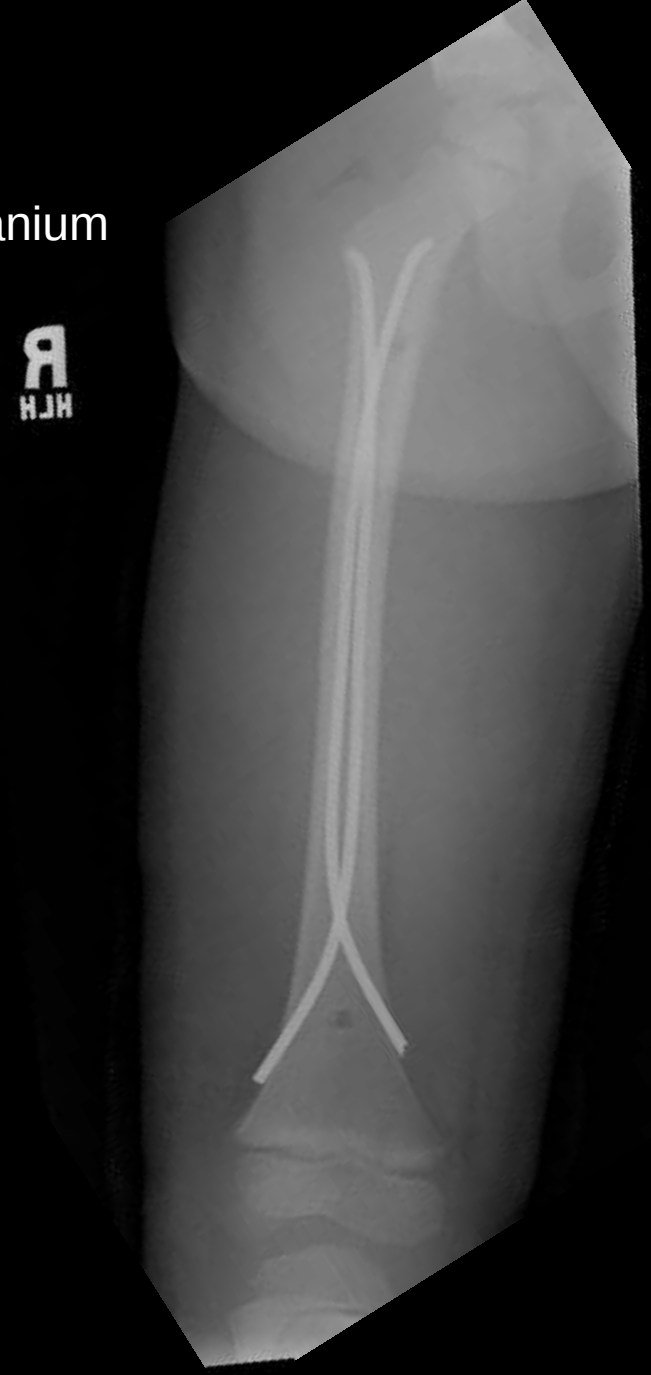

Children's Mercy
KANSAS CITY

3 months post op

Was walking and running in clinic without pain and with minimal limp

Leg alignment and length appeared symmetric

Discharged from clinic to follow up as needed

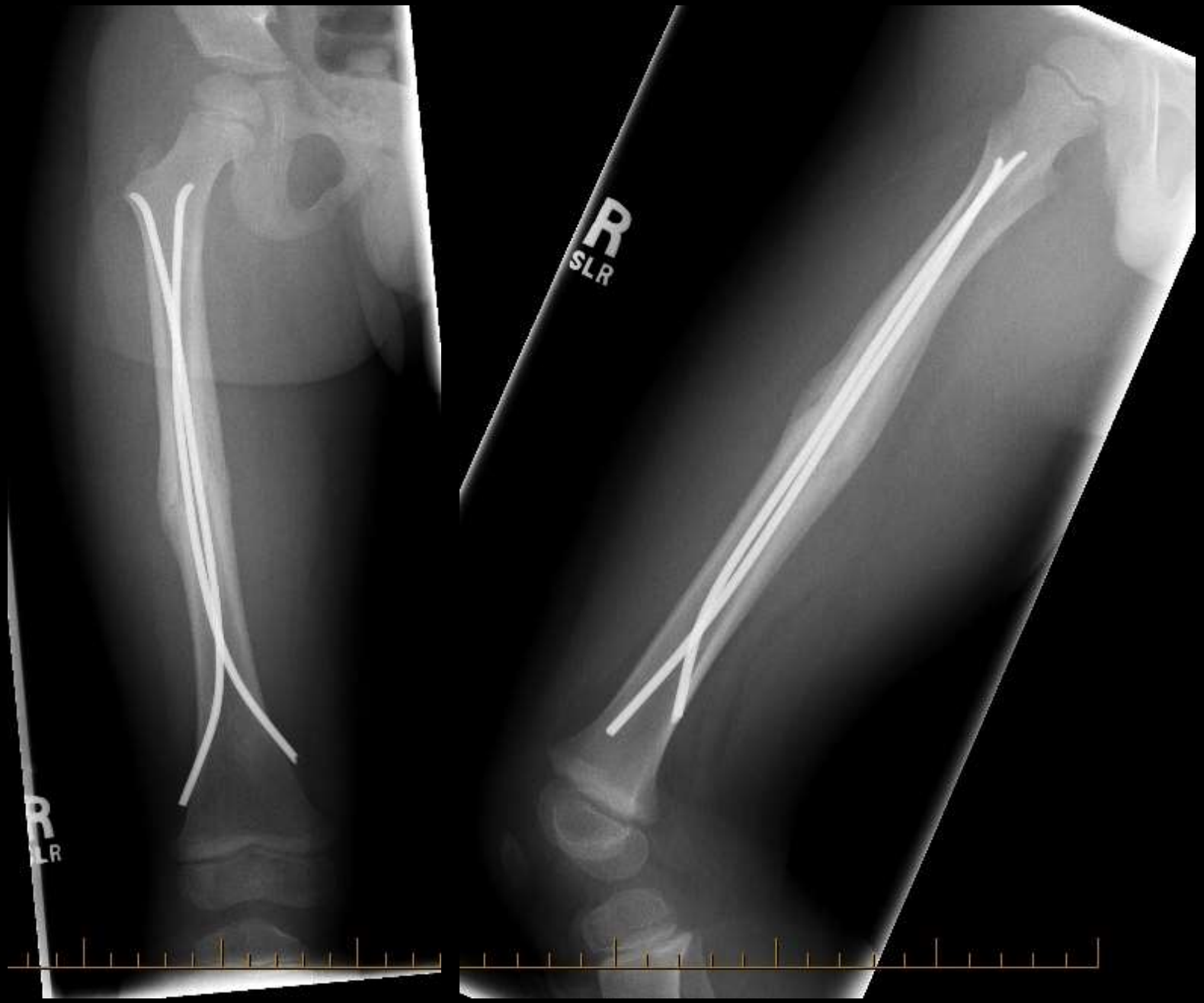

Returns 4 years and 1 month post injury

Complained of a limp and discomfort over the medial pin distally

Long leg standing film shows a 2 cm leg length discrepancy with the injured right side longer than the left. All the discrepancy is in the femur.

9 years 6 months of age

Skeletal age of 12.5 years

Femoral length discrepancy of 2.5 cm

Chronologic age 12.5 years

Children's Mercy KANSAS CITY

Make plans to do Right distal femoral epiphyseodesis at Age 13

Misses follow up

Returns at age 14 y 6 mo with an anterior inferior iliac spine avulsion

Right femur longer by 2.5-3.0 cm. Bone age approximately 15 years of age.

Children's Mercy
KANSAS CITY

Now 15 ½ years of age. Planned follow up in one year…

Case 9

6 y 6 mo male who was helping his dad build a carport when the roof of the structure fell on him

Otherwise healthy

Neurovascular exam of the limb intact

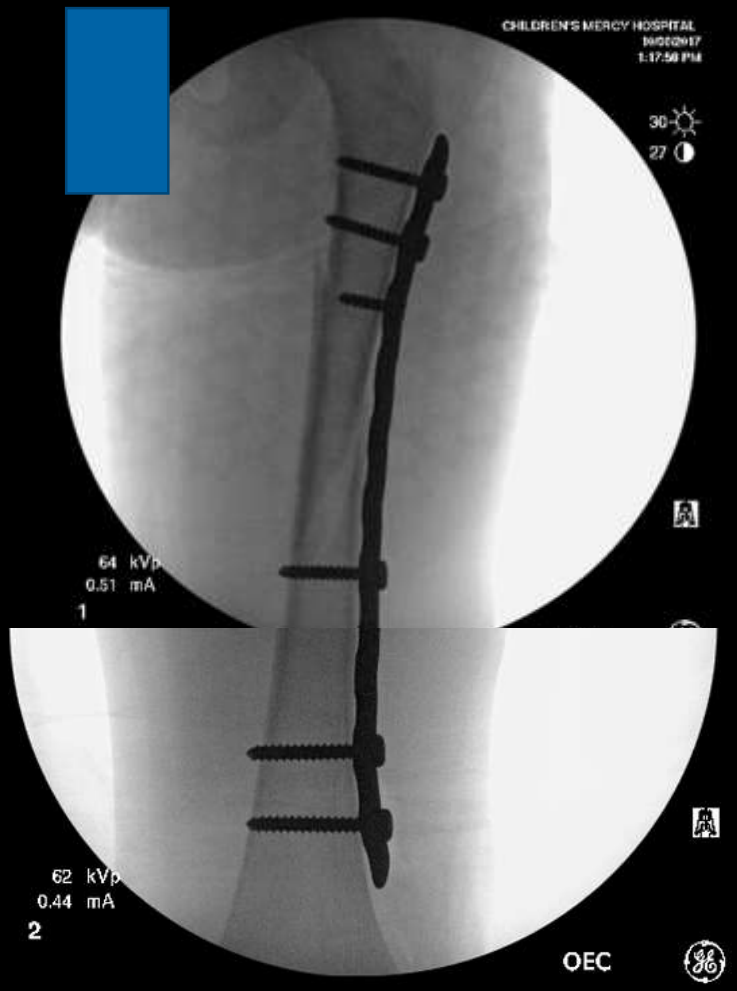

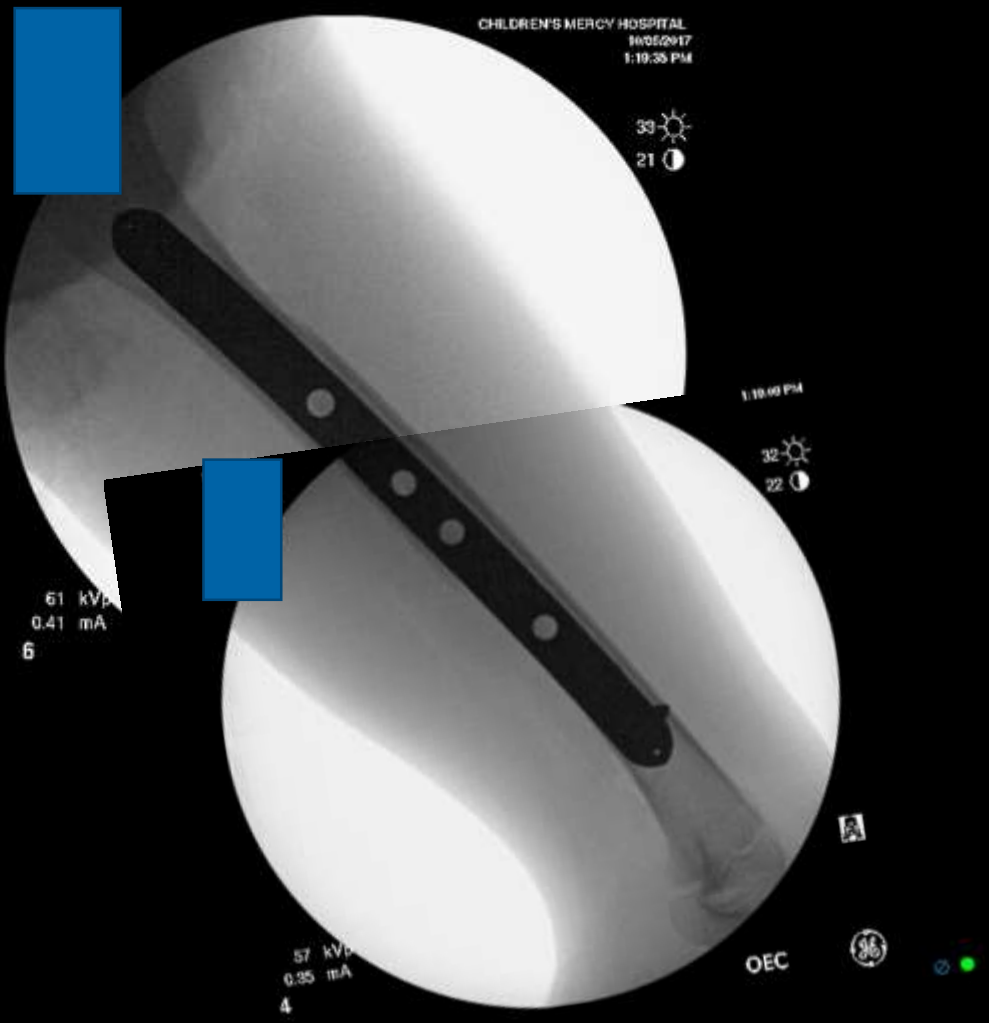

Underwent submuscular plating the following day

Children's Mercy
KANSAS CITY