Forearm Fracture Case Presentations

Children's Mercy Hospital

Kansas City, MO

Case 1

- 13y 6 mo old pre-menarchal female did a cartwheel in the street and sustained a midshaft radius and ulna fracture. She is RHD.
- Two poke holes were seen volarly on the involved forearm
- Limb neurovascular exam intact
- No other significant past medical history/no previous fractures
  - Below 3rd percentile for height and weight
  - Lives at teen facility
  - Previous cutting behavior, none currently

- Splinted in the ER and admitted to ortho service the evening of injury
- Administered Cefazolin q 8 hours
- Brought to the OR in the DOT room (post-call trauma room) the following morning for irrigation and debridement and reduction, possible fixation of the fractures

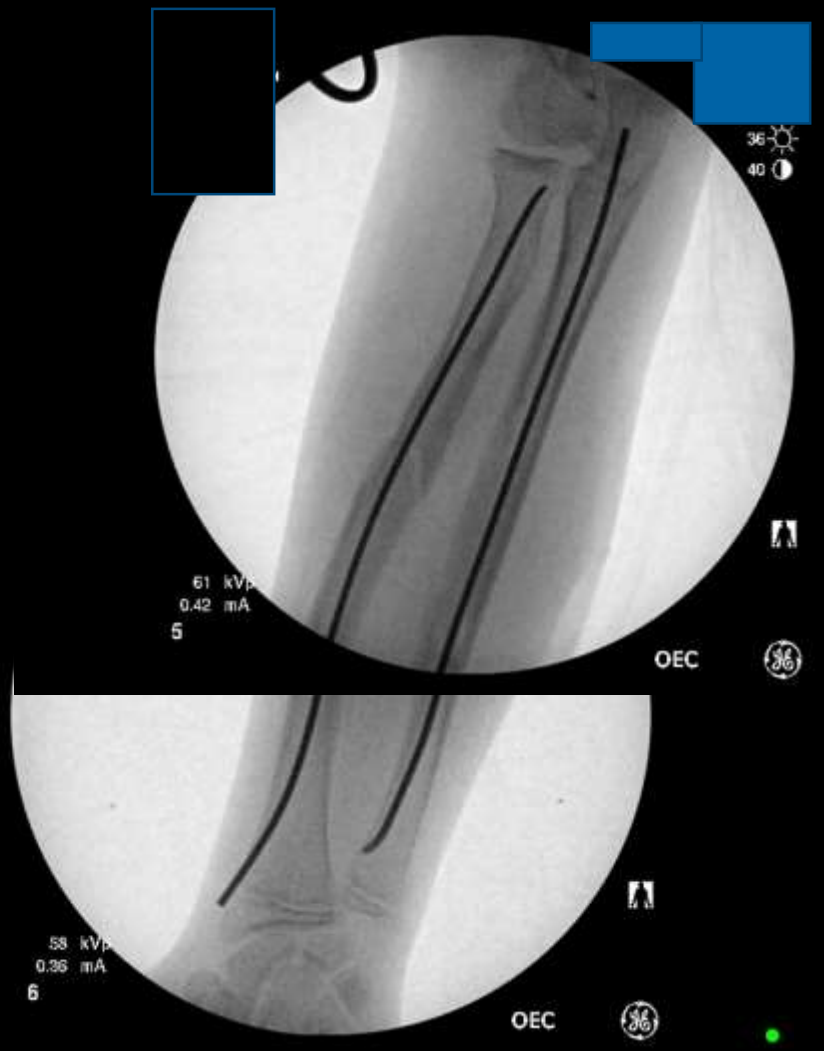

- Open wounds were extended and washed out with saline and an 18 gauge angiocath
- After irrigation, the volar compartment was felt to be very tense
- A volar fasciotomy was performed and treated with a negative pressure dressing. No dorsal fasciotomy or carpal tunnel release was felt necessary
- Returned to OR on POD #2 for removal of negative pressure dressing and delayed primary closure of 12 cm X 4cm fasciotomy wound

2 weeks post op

3 months post op

- Failed to keep follow up appointments after the 3 month follow up

Case 2

- 13 y 2 mo male fell off hoverboard and sustained a Grade 1 open radius and ulna shaft fracture
- Hx of asthma, otherwise healthy
- Limb neurovascular exam intact

- Given dose of Ancef at initial hospital, and then transferred to CMH for definitive care
- Underwent reduction and casting under sedation in ER
- Wound washed with saline and sterile dressing applied prior to casting
- Admitted to hospital for 48 hours (total) of antibiotics, and then discharged

Post-reduction xrays

After 6 weeks of cast immobilization

Wound healed

Neurovascular exam intact

Some irritation of the skin under the cast noted and diagnosed as “cellulitis”

Treated with oral Keflex

Forearm placed in removable brace

3 months post injury

Wearing forearm brace for sports activities only

Cellulitis resolved

No pain or apparent deformity

Near full rotation of forearm

Discharged from routine ortho f/u at this time

Case 3

9 y 10 mo male falls off his toy car and sustains a closed right midshaft radius and ulna fracture

No other notable PMH

No history of previous fractures

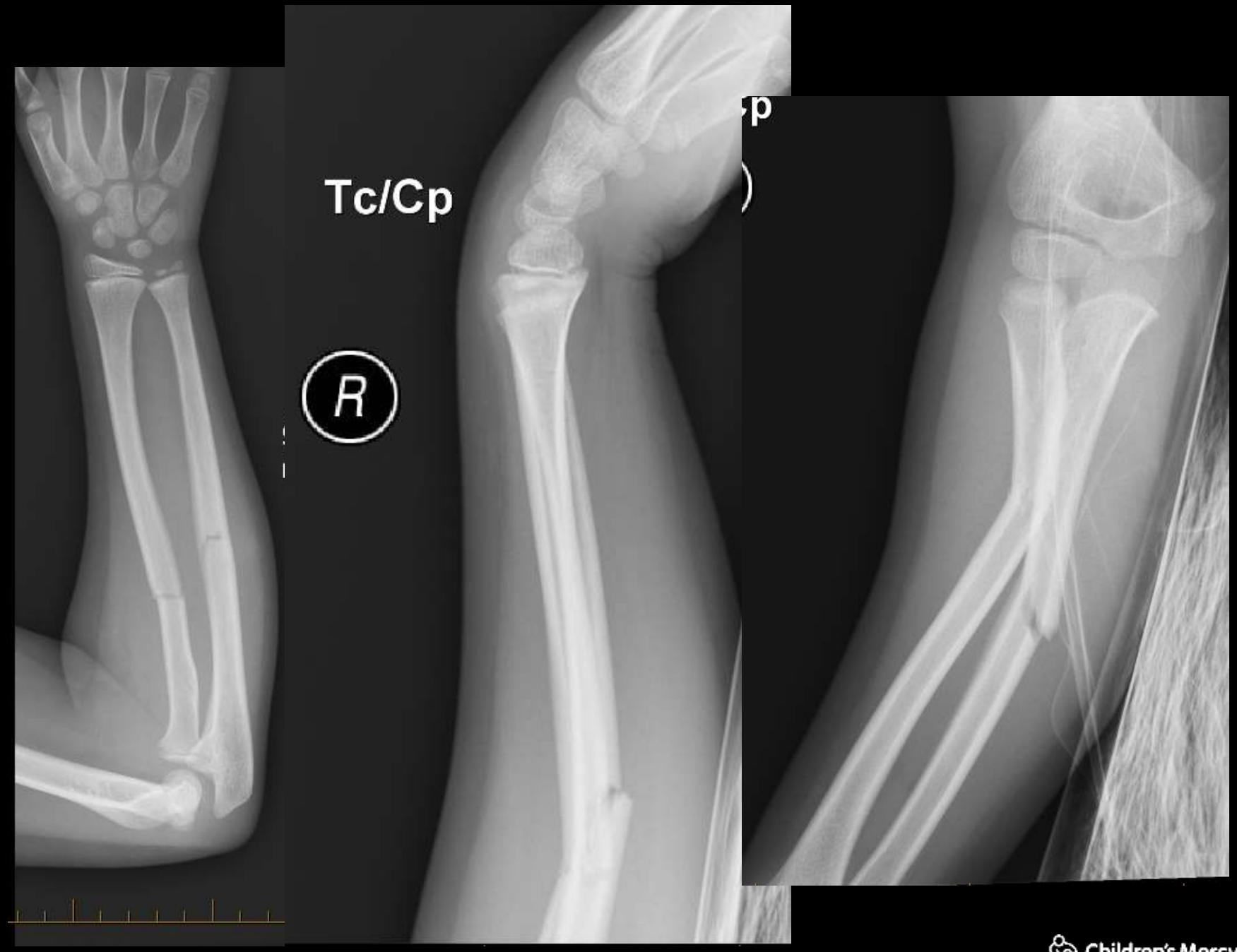

Children's Mercy
KANSAS CITY

Underwent closed reduction and casting at outside hospital

Was subsequently seen at two weeks post injury for follow up

2 weeks post injury

Taken out of cast at 4 weeks.

Presented to CMH ER for “2nd opinion.” Ulnar bowing was parents’ chief complaint.

Forearm rotation limited to 45 degrees of pronation and 45 degrees of supination. Elbow flexion/extension normal, and neurovascular exam intact

4 weeks post injury

45 days after original injury (6 weeks, 3 days),
underwent closed osteoclasis of forearm fracture and IM fixation with flexible titanium nails (2.0 mm) and long arm cast

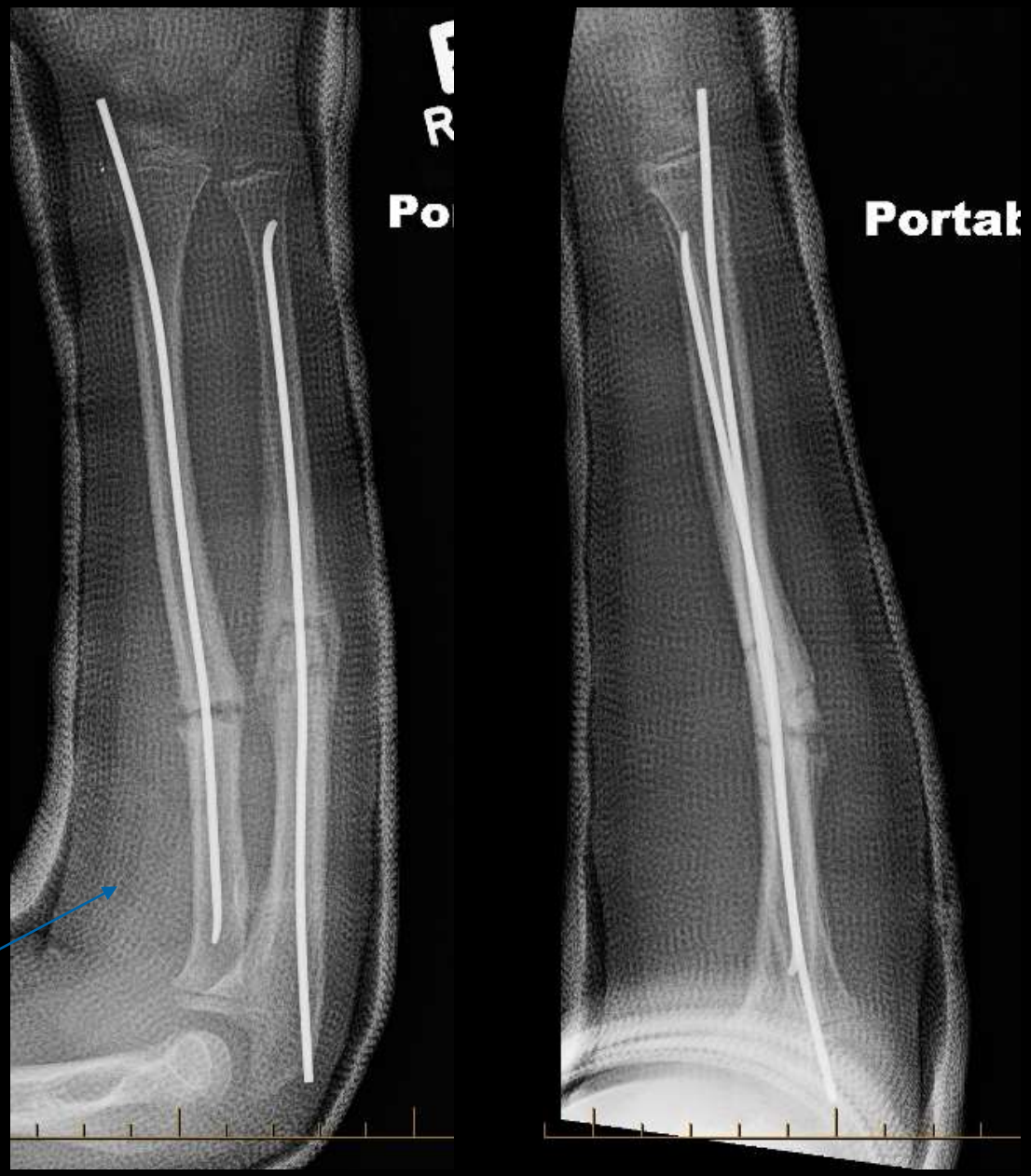

Immediate post op xrays

Immobilization discontinued 2 months post surgery

Had 80 degrees of supination and 70 degrees of pronation at this time

Flexible nails were removed 6 months post op (no xrays from that visit)

Lost to follow up after removal of the flexible nails

2 months post op

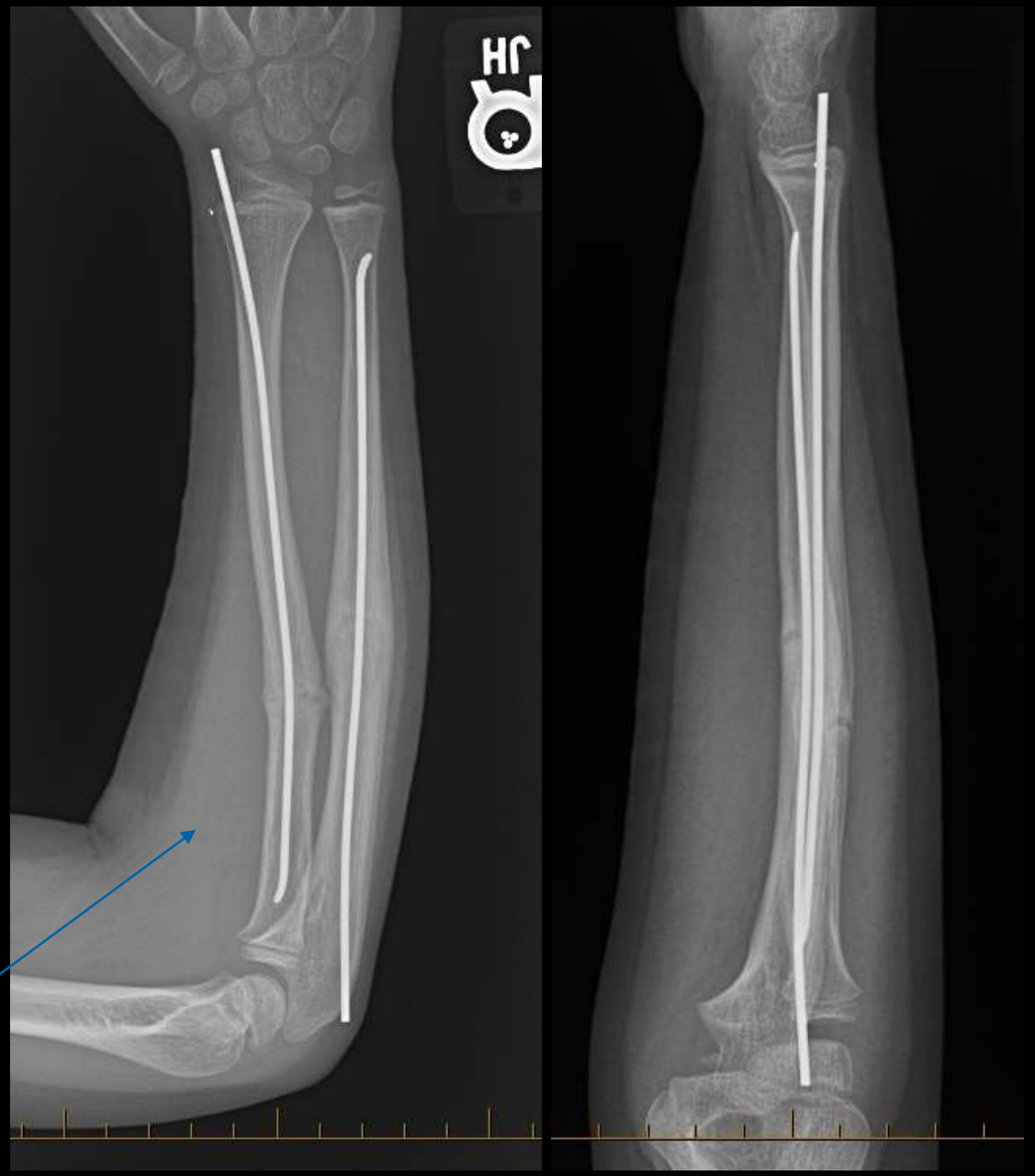

Case 4

- 6 y 4 mo RHD male falls from tree, landing on outstretched right arm
- Immediate pain and deformity
- Closed injury.
- NVI.
- Otherwise healthy.

Closed reduction performed in the ER and placed in long arm cast

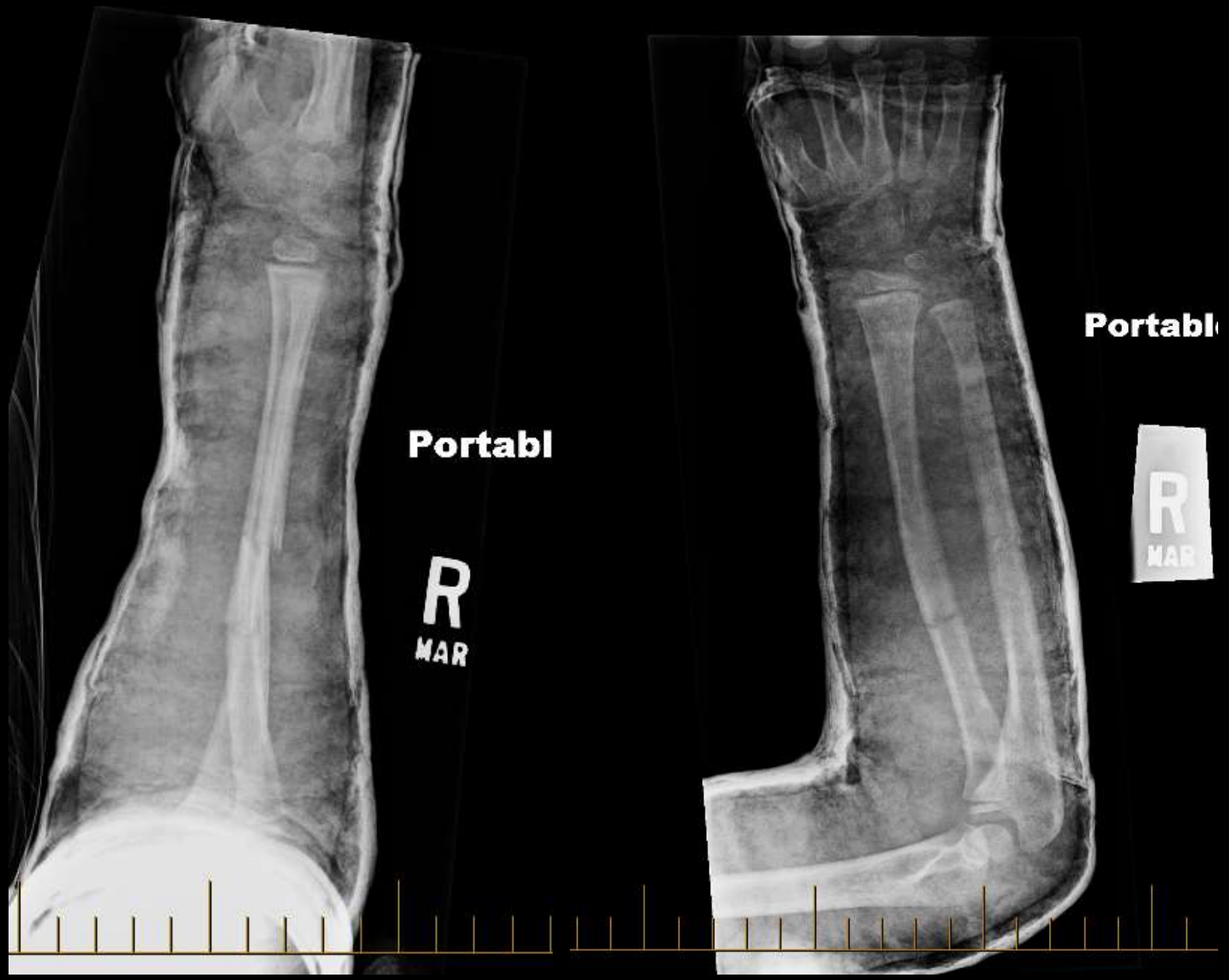

One week post reduction

Cast overwrapped with fiberglass at this time

2 weeks post reduction

Noted changing alignment, close follow up

- One month post reduction
- Clinical deformity and decreased supination/pronation seen on exam out of cast
- Radius: volar angulation approx 30 degrees
- Ulna: Ulnar angulation approx 20 degrees

- Plan for repeat closed reduction and casting under anesthesia with possible IM fixation

- On examination under anesthesia, he could pronate his arm but could supinate only to neutral.
- Fractures manipulated closed, found to be most adequately aligned in supination and extension
- Casted in extension with inclusion of thumb
- No internal fixation utilized

One week post op (5 weeks post injury)

3 weeks post op (7 weeks post injury)

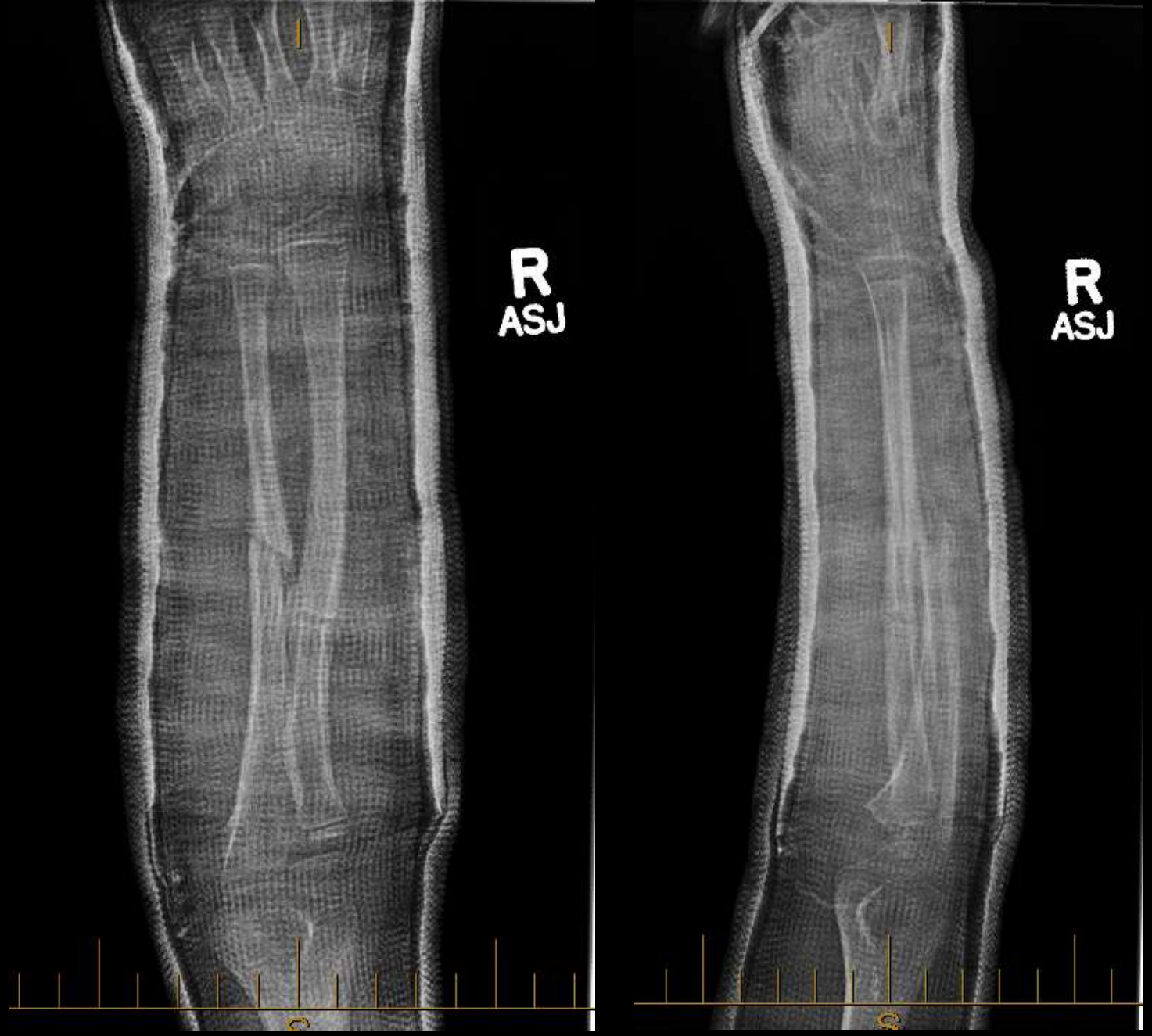

- Six weeks post op (2 ½ months post injury)
- Lacks 10 degrees of full supination and pronation
- Full flexion/extension of elbow
- Increasing callus formation
- Changed over to a forearm splint at this time

Three months post op (4 months post injury)

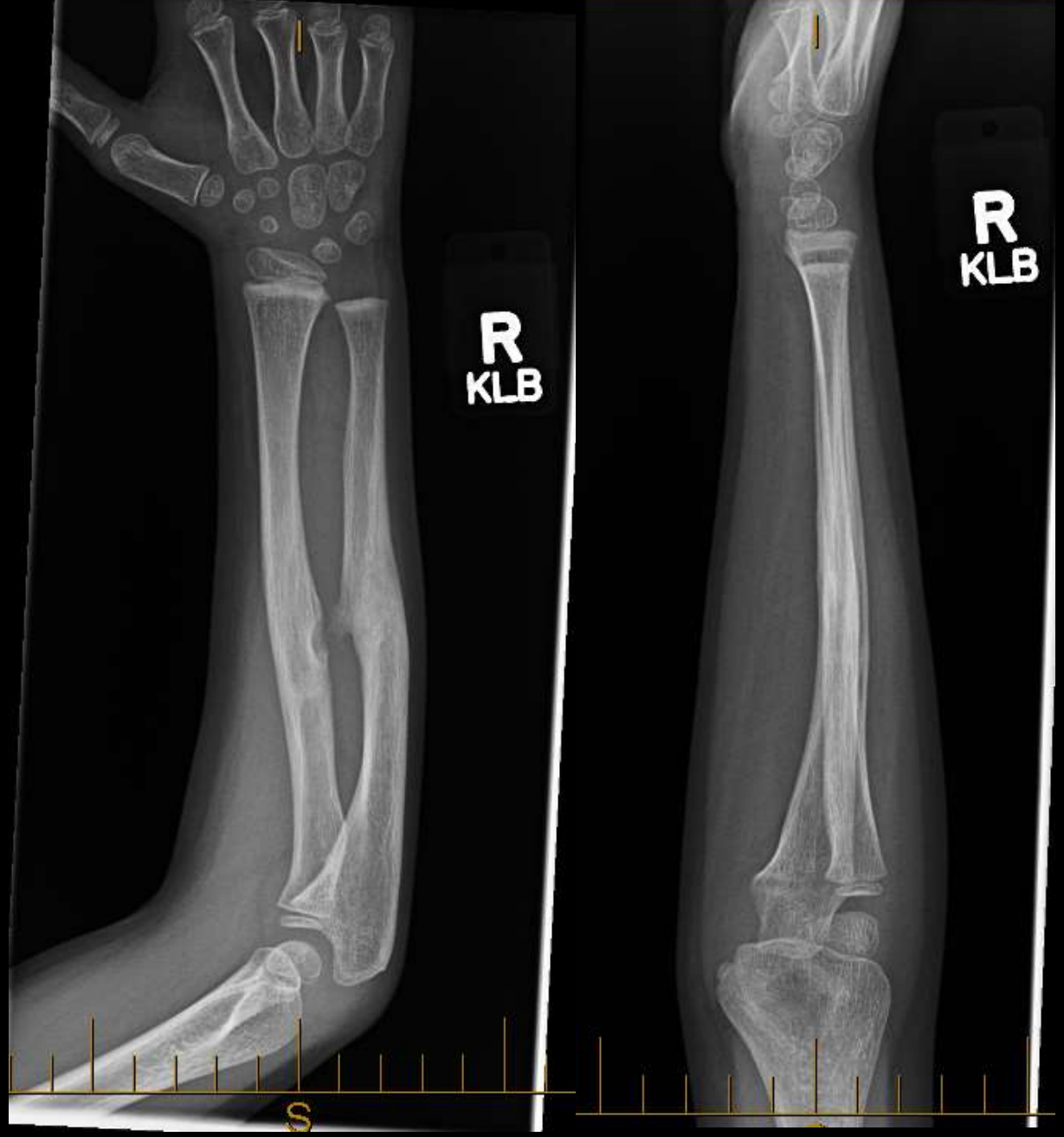

- 4 ½ months post op (5 ½ months post injury)
- Full pronation and supination of forearm
- Full flexion and extension of elbow
- Scheduled for 6 month remodeling check, but did not keep appointment

Case 5

- 11 y 2 mo old male fell off a skateboard and sustained a midshaft radius and ulna fracture.
- There was a tiny (1 mm) wound on the volar surface of the forearm which continued to ooze.
- Pt. otherwise healthy. No neurologic or vascular injury to forearm
- Administered cefazolin in ER

Splinted, admitted, and brought to OR the following day for wound evaluation and fracture reduction.

Wound was felt to communicate with radius fracture.

Washout done with 300cc fluid and fracture reduced and casted without fixation

Discharged home after 24 hours of antibiotics post op

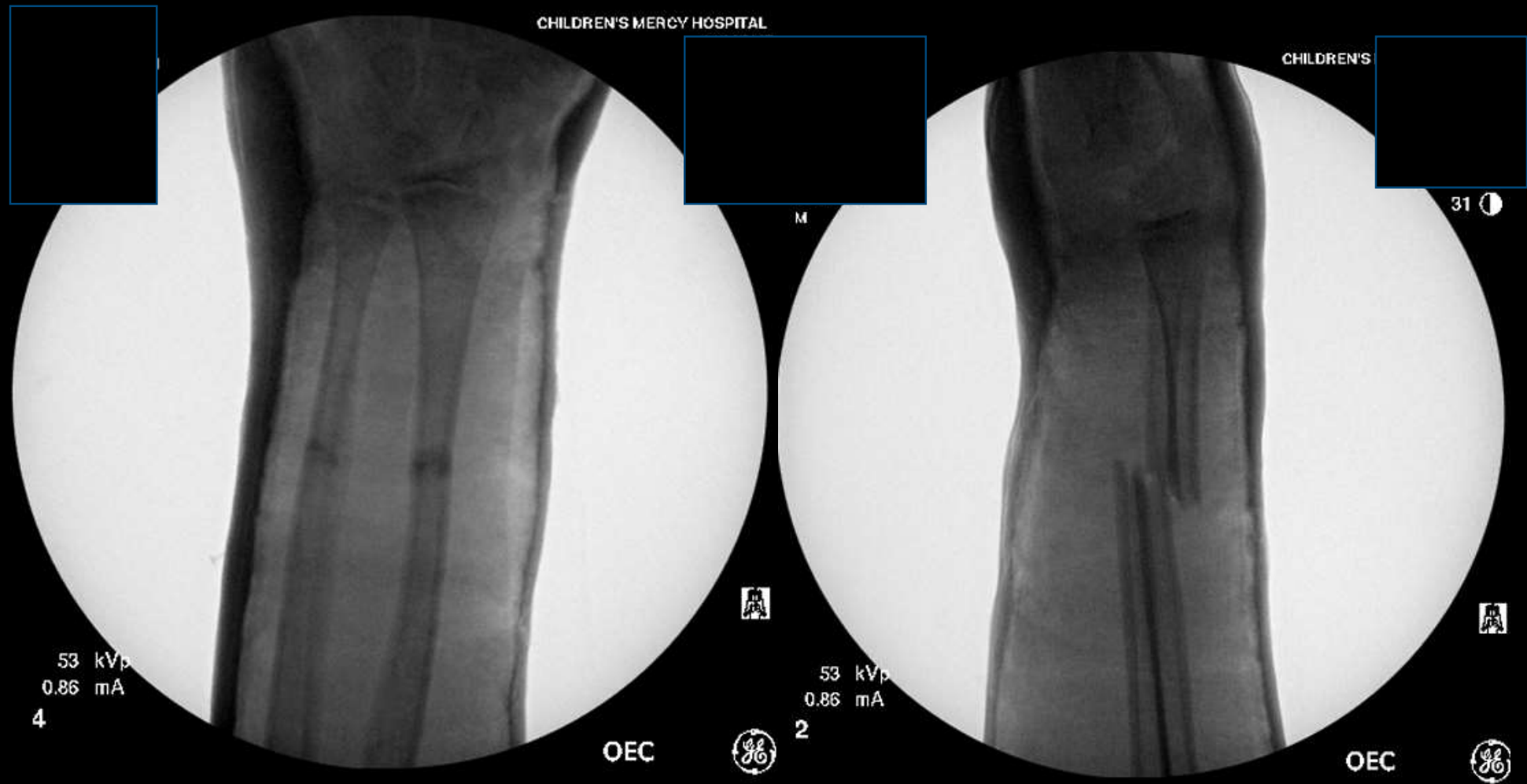

One week after reduction and casting

5 weeks after reduction and casting

Transitioned to forearm brace

10 weeks after reduction and casting

Lacks last 10 degrees of pronation/supination. No pain. No apparent deformity.

Instructed to wear his forearm brace for activities for 2 more months

Did not return for further F/U

Case 6

- 10 y 10 mo RHD male fell while doing a flip on a trampoline and sustained a closed right midshaft radius and ulna fracture
- NVI
- History of asthma, but otherwise healthy

Underwent closed reduction and casting in the ER on the night of injury

One week post-reduction

Two weeks post-reduction

One month post-reduction

Two months post-reduction

5 months post-reduction

Using a brace for all activities as is hesitant to take it off

Full pronation and supination

Instructed to use brace for sports only for one month and then discontinue brace at 6 months post-injury

- 6 months and one day after his original fracture and reduction, he was riding his friend’s hoverboard and fell. He was not wearing the brace at the time.

Post-reduction views on day of new injury

- Cast revised two weeks post re-injury

- 2 ½ months post re-fracture. Cast removed, and placed back in forearm brace.
- No pain. Full pronation and supination on examination.

4 months post re-fracture (10 months post initial injury)

Full forearm pronation and supination

No pain with activities

Uses brace for PE and outdoor play only

Taking 2,000 units of Vitamin D daily

Started doing push ups to increase weightbearing exercise to upper extremities

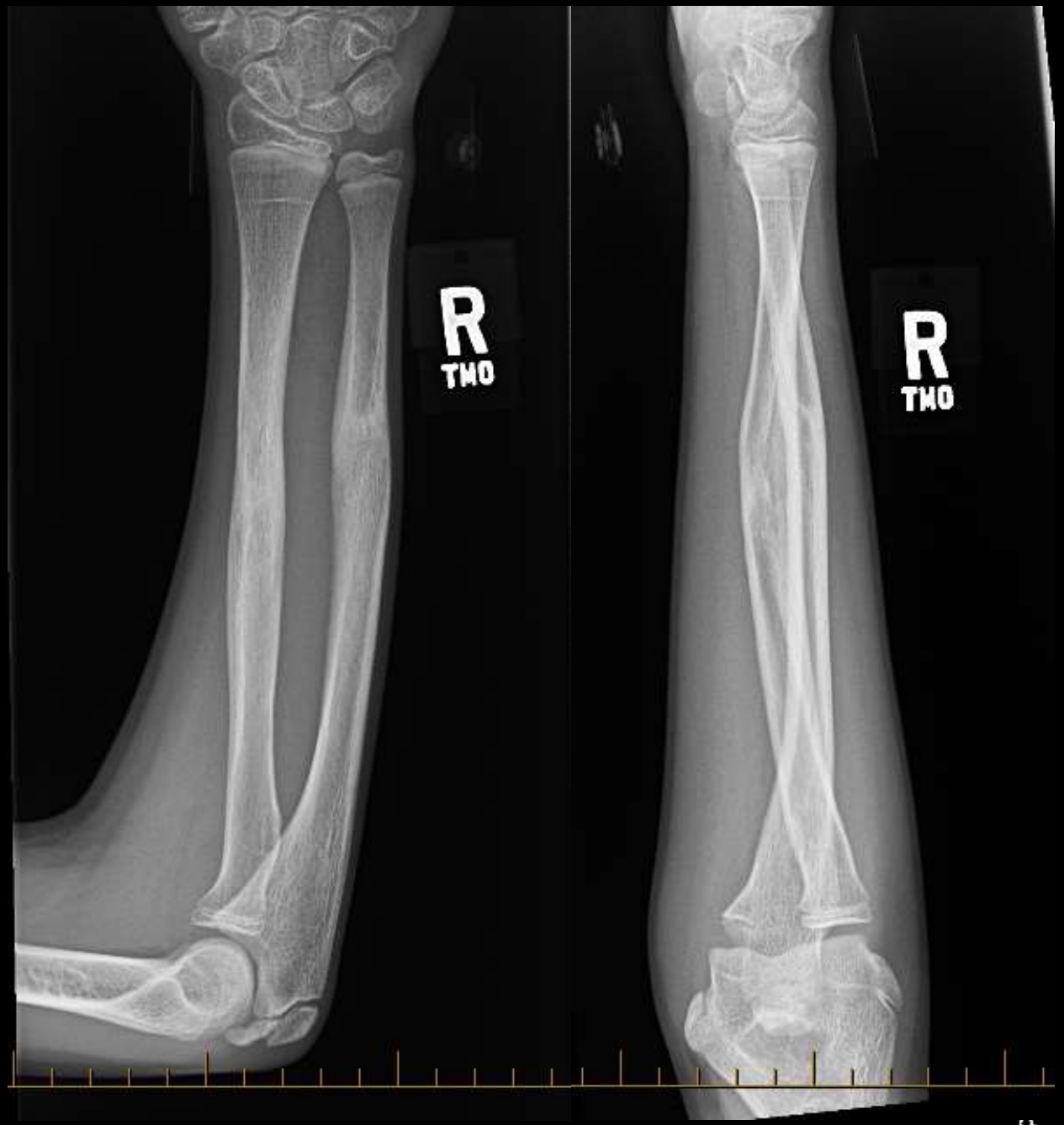

Children's Mercy
KANSAS CITY

Case 7

- 11 y 6 mo old RHD male bitten by family dog (German Shepard/Lab mix)
- Dog's immunizations "up-to-date"
- NVI
- No associated injuries
- Otherwise healthy

AP and lateral forearm xray at referring hospital on day of injury

Received Ancef and gentamicin at OSH. Splinted and transferred.

- Started on antibiotics to cover Pasturella and gram negative bacteria (Unasyn and Rocephin)
- Arm wounds dressed and fracture splinted
- Brought to the OR the next morning for irrigation and debridement of wounds with primary closure, and stabilization of the ulna fracture with a flexible IM nail (titanium 2.5 mm)
- Antibiotics continued 48 hours post op

- Seen one week post injury
- Wounds have some serosanguinous drainage but no cellulitis or purulence
- Neurovascular exam intact
- Wounds dressed and placed in long arm cast

Children's Mercy
KANSAS CITY

3 weeks post injury

Wounds healing well.
No drainage.
Clean, closed, and dry.

Pain improved

Converted to a short arm cast

Children's Mercy
KANSAS CITY

- 6 weeks post injury
- Wounds healed
- Minimal pain
- Placed in a cock-up wrist splint which he is allowed to take off for bathing, swimming, and sleeping

- Now 3 months post injury
- Wounds clean, closed, and dry
- Pain w/palpation of fracture site
- Lacks 10 degrees of full supination/pronation
- Started taking Vitamin D and calcium 9 weeks post op

- Requires removal of flexible nail and compression plating to resolve ulna non-union
- After that procedure has full rotation of forearm and returns to regular activity

Case 8

- 22mo female fell off hammock 1 day prior
- Immediate pain and refusal to use
- Presented to ED as the pain was keeping her awake
- Hx of asthma, otherwise healthy
- Mild clinical deformity, pain with manipulation
- 22 degrees ulna
- 14 degree radius
- Placed in splint

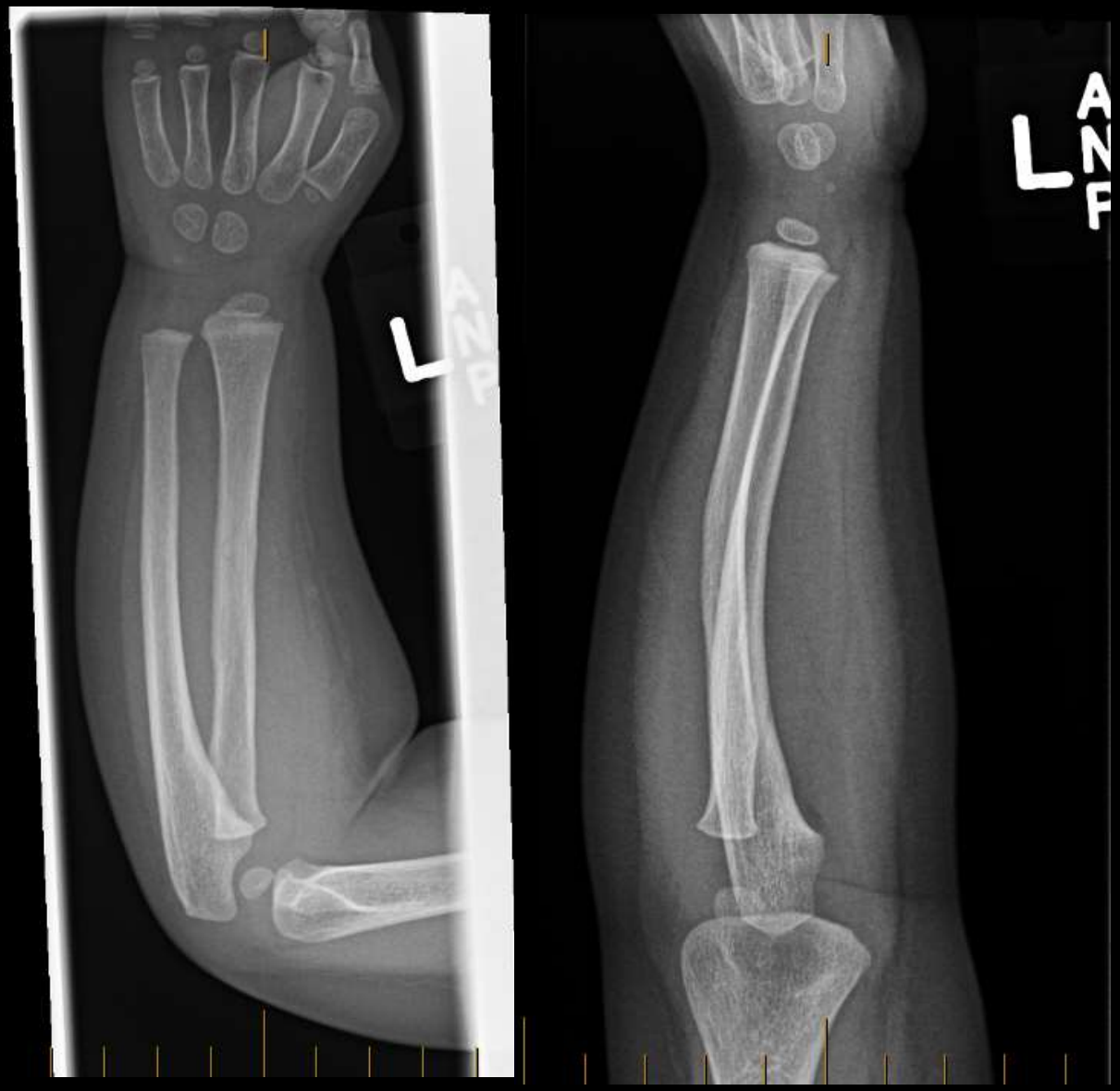

OR the next day

- Apex dorsal deformity, lacked 45 degrees of full supination
- Apex of the angulation was reduced with slow gradual pressure
- Radial fracture completed
- Long arm cast in full supination

3 weeks post op
Remain in Cast

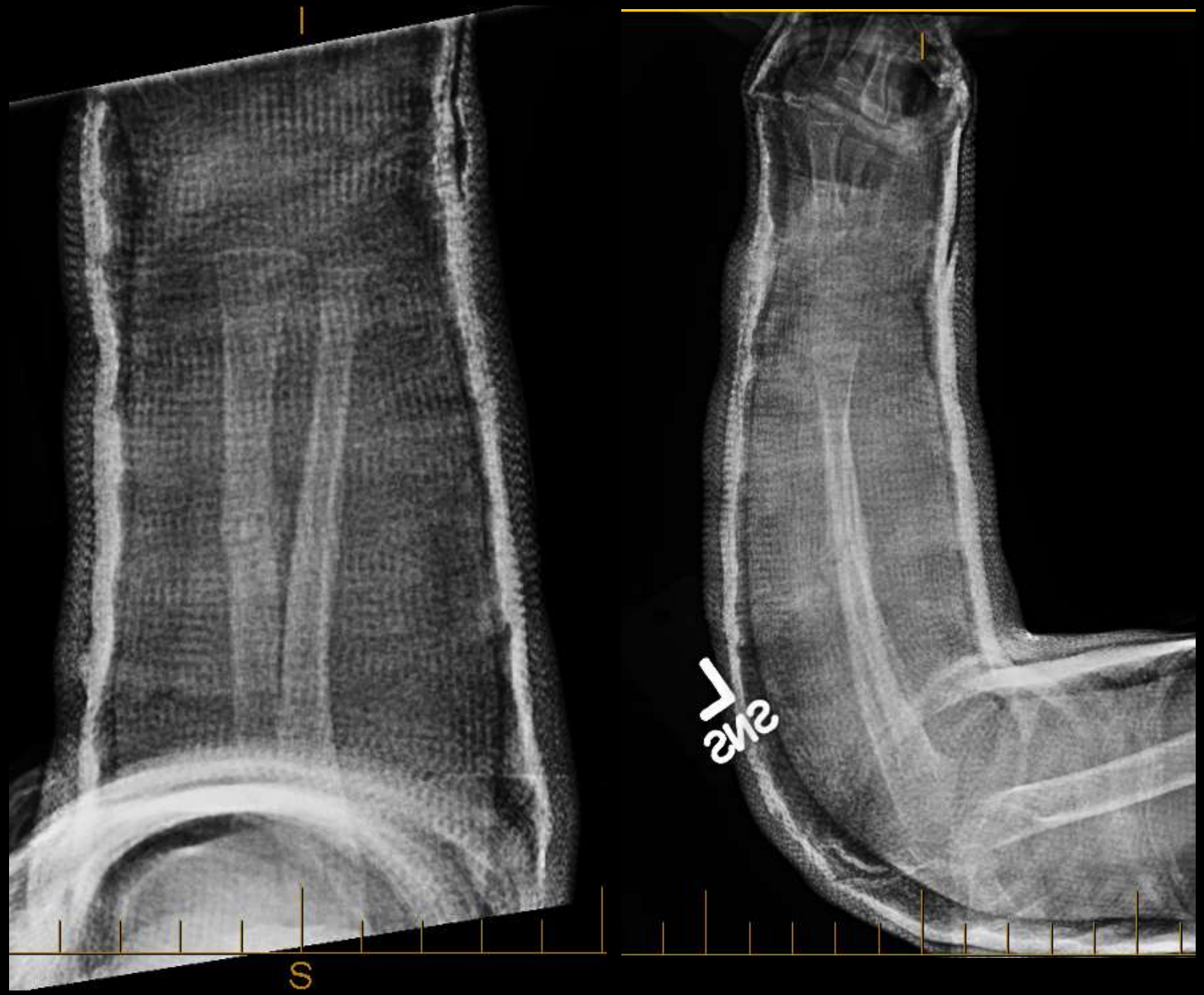

6 weeks post op

- Full supination and pronation
- Full elbow flexion/extension
- Released from care

Case 9

- 9 y 1 mo old male who was going down a firepole on a playground when he got his left arm caught in a metal grate adjacent to it
- He was dangling with all his body weight hanging by his broken arm
- Left arm neurovascular exam intact
- Otherwise healthy
- Due to swelling, he was splinted and brought in the following week for reduction under anesthesia

- The following week, he underwent “single bone fixation” of his forearm fracture
- An open reduction of the ulna and intramedullary fixation with a 3.0 mm titanium flexible nail was done
- Placed in a bivalved long arm cast

Children's Mercy
KANSAS CITY

3 weeks post op

Cast changed at this visit

6 weeks post op

Left in waterproof long arm cast as family was going on a summer trip to Florida

3 months post op

Taken out of his short arm waterproof cast

Placed in a forearm brace and allowed to participate in recess and PE with brace on

Children's Mercy
KANSAS CITY

8 months post op

Has full supination

Lacks last 15 degrees of pronation

Participating in all activities

Ulnar pin subsequently removed

- 22 months post op, and one month post ulnar pin removal
- Still lacks 10 degrees of pronation, but full supination
- Discharged from care at this visit