

# Minimally Invasive Bar Repair for 'Redo' Correction of Pectus Excavatum

By K.A. Miller, D.J. Ostlie, K. Wade, B. Chaignaud, G.K. Gittes, W.M. Andrews, K.W. Ashcraft, R.J. Sharp, C.L. Snyder, and G.W. Holcomb III  
Kansas City, Missouri

**Background/Purpose:** A small percentage of patients who have undergone traditional, "Ravitch-type" pectus excavatum repair present with unsatisfactory results and require a second procedure for correction. Reoperative open surgery for pectus excavatum has been associated with extensive dissection and substantial blood loss. The minimally invasive (MIS) bar repair for the correction of pectus excavatum has been gaining acceptance. This study evaluates the authors' results with patients who have undergone the MIS bar repair for redo correction of their pectus excavatum.

**Methods:** A retrospective chart review of all patients undergoing MIS bar repair between December 1997 and August 2001 was performed. Information about demographics, deformity, operative course, complications, and early outcome was recorded.

**Results:** Ninety-two patients underwent MIS repair during this period. Ten patients had redo MIS bar repair for unsatisfactory prior open correction. Operating time was 52 minutes for standard patients and 70 minutes for the redo patients ( $P < .001$ ). Blood loss and postoperative hospitalization were similar between groups.

**Conclusion:** The minimally invasive pectus repair can be performed safely with minimal blood loss and short operating time in patients who have undergone prior unsatisfactory open repair of pectus excavatum and can be an alternative approach to reoperative open repair in these patients.  
*J Pediatr Surg* 37:1090-1092. Copyright 2002, Elsevier Science (USA). All rights reserved.

**INDEX WORDS:** Pectus excavatum, minimally invasive, reoperative surgery.

**P**ECTUS EXCAVATUM is the most common chest wall deformity in children. Since its introduction by Nuss et al<sup>1</sup> in 1997, the minimally invasive (MIS) pectus bar repair for correction of pectus excavatum has been gaining acceptance among pediatric surgeons and their patients. This technique helps avoid extensive dissection and involves the placement of a convex substernal bar principally through 2 lateral chest wall incisions. It has been associated with short operating times, minimal blood loss, and good cosmetic results in reported studies.<sup>1-3</sup> Until this time, the standard repair has involved an open procedure based on that described by Ravitch,<sup>4</sup> which involves subperichondrial resection of abnormal costal cartilages.<sup>5</sup> A small percentage of patients who have undergone traditional, "Ravitch-type" pectus excavatum repair present with unsatisfactory results and require a second, redo procedure for correction.

Reoperative open surgery for pectus excavatum has been associated with extensive dissection and substantial blood loss.<sup>6</sup> This study evaluates our results with patients who have undergone the minimally invasive bar repair for re-do correction of their pectus excavatum.

## MATERIALS AND METHODS

All patients with pectus excavatum repaired at Children's Mercy Hospital in Kansas City, Missouri between December 1997 and August 2001 were selected for a retrospective chart review. This review was initiated as a quality assurance (QA) monitor; therefore, IRB approval could not be obtained after the QA chart review had occurred. Patient selection for corrective repair was based on history, physical examination, plain radiographs, and selective computed tomography (CT). The deformity classification was based on assessment of plain films in the majority of cases, or CT with a ratio of transverse diameter to anteroposterior diameter (distance between posterior sternum and anterior vertebral body) greater than 3.25 defining a severe deformity.<sup>7</sup>

The minimally invasive repair required small (2 cm), bilateral, midaxillary transverse incisions, subcutaneous tunneling, and intrathoracic or extrapleural placement of a substernal convex stainless steel bar (Walter Lorenz Co, Jacksonville, FL). This bar was bent to conform to the patient's anterior chest wall. Lateral stabilizer bars have been used routinely since September 1999. Also, since the autumn of 1999, the routine modification of a vertical subxiphoid anterior chest wall incision has been added to our repair technique (Fig 1). This modification involves the creation of a small subxiphoid pocket within the anterior mediastinum to visualize the passage of the bar at this location. Two to 3 years after their initial MIS procedure, patients are scheduled electively for removal of the bar as an outpatient operation.

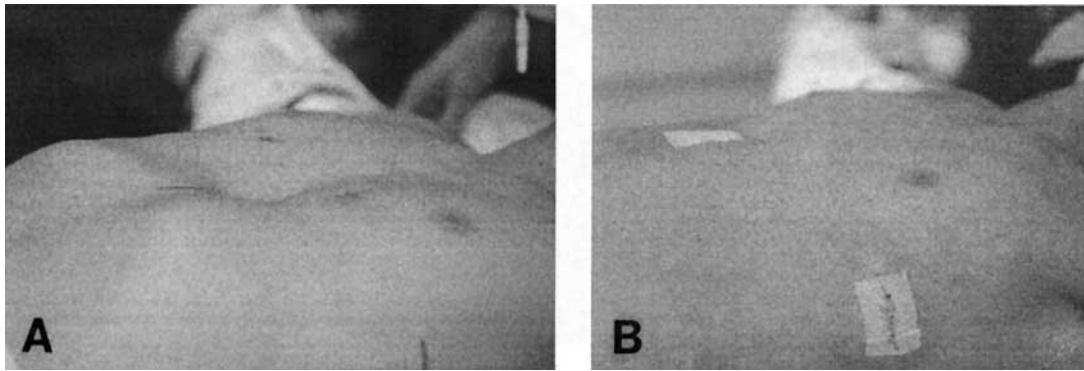
Information about patient demographics, degree of deformity, operative course, complications, and initial outcome was recorded. Statis-

From The Children's Mercy Hospital, University of Missouri at Kansas City School of Medicine, Kansas City, MO.

Presented at the 53rd Annual Meeting of the Section on Surgery of the American Academy of Pediatrics, San Francisco, California, October 19-21, 2001.

Address reprint requests to G.W. Holcomb III, MD, Department of Surgery, The Children's Mercy Hospital, 2401 Gillham Rd, Kansas City, MO 66408.

Copyright 2002, Elsevier Science (USA). All rights reserved.  
0022-3468/02/3707-0032\$35.00/0  
doi:10.1053/jpsu.2002.33883



**Fig 1. Illustration of our modified MIS pectus repair. (A) lateral view of the deformity; (B) lateral view after our modified MIS procedure. Note the small subxiphoid incision.**

tical analysis was performed using the Student's *t* test. A *P* value less than .05 was considered significant.

**RESULTS**

Ninety-two patients underwent MIS pectus bar repair during this period. Ten patients had redo MIS bar repair for unsatisfactory prior open repair. All patients requiring reoperation were classified with moderate or severe recurrent pectus deformity. Mean age was 11.4 years for first-time (standard) MIS patients and 15 years for redo patients (*P* < .03). Patients underwent redo procedures, on average, 9 years after their initial repair. Short-term results of the MIS pectus bar repair in these groups are illustrated in Table 1. Operating time was 52 minutes for standard patients and 70 minutes for redo patients (*P* < .001). Blood loss was not statistically different between groups with 0.5 mL/kg average estimated blood loss for the standard group and 0.8 mL/kg for patients undergoing redo pectus repair. Postoperative hospitalization was similar between groups with 3.7 days for the standard group versus 3.4 days for the redo group.

The complication rate for patients undergoing initial MIS repair was 12% (Table 2). There were no operative complications involving patients having redo MIS pectus excavatum repair, and clinical results have been good to excellent in all redo patients over an average 23-month follow-up. Over 95% of all patients undergoing the minimally invasive repair have reported satisfaction with their postoperative results, and greater than 93% have shown good to excellent correction of their chest wall deformity. Three of the 10 patients in the redo group

have undergone bar removal, and all have had a good to excellent clinical result.

**DISCUSSION**

The minimally invasive procedure for correction of pectus excavatum initially described by Nuss et al<sup>1</sup> was founded on the ability of the chest wall to reconfigure and remodel. This technique has multiple advantages over the traditional open procedure; however, long-term follow-up has not been possible for most patients because of its recent development. Many institutions are evaluating this technique to identify appropriate patient selection and application.<sup>2,3,8-10</sup> This retrospective study attempts to evaluate the application of the minimally invasive bar repair of pectus excavatum (and chest wall pliability) for patients who have undergone previous open correction. Although there is a limited duration of follow-up and a small study group, we are encouraged by our early results.

In 1999, we modified our MIS procedure to include a subxiphoid incision for the creation of a substernal pocket within the mediastinum.<sup>3</sup> We feel that this modification of the original described procedure diminishes the chance of serious injury to the heart or pericardium as the bar is passed under the sternum and through the mediastinum. Other investigators report the use of thoracoscopy to assist with safe bar passage.<sup>2,8,10</sup> The subxiphoid incision was performed in all patients undergoing redo surgery without difficulty.

**Table 1. Short-Term Results for Open Versus MIS Bar Repair of Pectus Excavatum**

	Standard Repair (n = 82)	Redo Repair (n = 10)	
Operating time (mean, min)	54	70	<i>P</i> < .001
Blood loss (mean, mL/kg)	0.5	0.8	
Length of stay (d)	3.7	3.4	

**Table 2. Complications Noted in Patients Undergoing Initial MIS Pectus Excavatum Repair**

Complication	No. of Patients
Pectus bar displacement (that required reoperation)	5
Pneumothorax (that required tube thoracostomy)	2
Hemothorax/pleural effusion	1
Pericarditis	1
Infectious complications	1

Like many other institutions, we experienced a learning curve during the early application of this technique.<sup>2,3,8-10</sup> Over 60% of our complications occurred during our first 9 months of experience. This is reflected in our 12% complication rate for first-time repairs. The routine use of lateral stabilizing bars also has reduced our early complications related to rotational or lateral bar displacement. The first re-do procedure was performed 9 months after beginning to utilize this procedure at our institution.

Re-do MIS procedures have been found to require slightly more operating time compared with first-time MIS repairs, but this operating time is significantly shorter than the average time of 143 minutes previously reported by us to perform a traditional, "Ravitch" operation.<sup>3</sup> Ellis et al<sup>6</sup> described good to excellent results in

16 of 16 patients undergoing re-do open correction for pectus excavatum; however, they also described significant intraoperative dissection and a 55% transfusion rate in these patients.

For children with the difficult problem of recurrent pectus excavatum after open repair, the minimally invasive bar repair is a viable alternative to a re-do traditional "Ravitch-type" open repair. This MIS technique can be performed safely with minimal blood loss and relatively short operating time despite previous chest wall surgery. A short-term analysis of the quality of repair, including absence of preoperative symptoms, patient satisfaction, and cosmetic appearance also is quite encouraging in this group. We believe the minimally invasive approach is the procedure of choice for patients with unsatisfactory previous open repair of pectus excavatum.

#### REFERENCES

1. Nuss D, Kelly RE, Croitoru DP, et al: A 10-year review of a minimally invasive technique for the correction of pectus excavatum. *J Pediatr Surg* 33:545-552, 1998
2. Hebra A, Swoveland B, Egbert M, et al: Outcome analysis of minimally invasive repair of pectus excavatum: Review of 251 cases. *J Pediatr Surg* 35:252-258, 2000
3. Miller KA, Wood RK, Sharp RJ, et al: Minimally invasive bar repair of pectus excavatum: A single institution's experience. *Surgery*, 130:652-659, 2001
4. Ravitch MM: The operative treatment of pectus excavatum. *Ann Surg* 129:429-444, 1949
5. Shamberger RC, Welch KJ: Surgical repair of pectus excavatum. *J Pediatr Surg* 23:615-622, 1988
6. Ellis DG, Snyder CL, Mann CM. The 're-do' chest wall deformity correction. *J Pediatr Surg* 32:1267-1271, 1997
7. Haller JA Jr, Kramer SS, Lietman SA: Use of CT scans in selection of patients for pectus excavatum surgery: A preliminary report. *J Pediatr Surg* 22:904-908, 1987
8. Engum S, Rescorla F, West K, et al: Is the grass greener? Early results of the Nuss procedure. *J Pediatr Surg* 35:246-251, 2000
9. Moss RL, Albanese CT, Reynolds M: Major complications after minimally invasive repair of pectus excavatum: Case reports. *J Pediatr Surg* 36:155-158, 2001
10. Molik K, Engum S, Rescorla F, et al: Pectus excavatum repair: Experience with standard and minimal invasive techniques. *J Pediatr Surg* 36:324-328, 2001
11. Haller JA Jr, Scherer LR, Turner CS, et al: Evolving management of pectus excavatum based on a single institutional experience of 664 patients. *Ann Surg* 209:578-583, 1989
12. Fonkalsrud EW, Dunn JC, Atkinson JB: Repair of pectus excavatum deformities: 30 years of experience with 375 patients. *Ann Surg* 231:443-448, 2000
13. Haller JA: Severe chest wall constriction from growth retardation after too extensive and too early (<4 years) pectus excavatum repair: An alert. *Ann Thorac Surg* 60:1857-1864, 1995